

## A three-unit posterior resin-bonded fixed partial denture seated one year after extraction of second molar: A clinical report

Hiroyasu Koizumi, DDS, PhD,<sup>a,b</sup> Naomi Tanoue, DDS, PhD,<sup>c</sup> Daisuke Nakayama, DDS,<sup>a</sup> Takaya Ishii, DDS,<sup>a</sup> and Hideo Matsumura, DDS, PhD<sup>a,b</sup>

<sup>a</sup>Department of Fixed Prosthodontics, and <sup>b</sup>Division of Advanced Dental Treatment, Dental Research Center, Nihon University School of Dentistry, Tokyo, and <sup>c</sup>Nagasaki University Hospital of Medicine and Dentistry, Nagasaki, Japan

This article reports a resin-bonded fixed partial denture (RB-FPD) applied to a diabetic. Before seating the RB-FPD, a removable partial denture was used for about one year after extraction of a second molar. The RB-FPD framework was cast from silver-palladium-copper-gold alloy (Castwell M.C. 12), and the surface to be bonded was air-abraded with alumina. The RB-FPD was then treated with a metal priming agent (V-Primer), and bonded with an adhesive resin (Super Bond Opaque). After an observation period of six years and six months, the FPD was functioning satisfactorily. The materials and procedures reported here are applicable as an option for a prosthodontic treatment for medically compromised patients. (*Int Chin J Dent* 2009; 9: 15-18.)

**Key Words:** adhesive, alloy, primer, resin-bonded fixed partial denture, removable denture.

### Introduction

Replacement of missing teeth in the posterior region is important for recovering tooth anatomic form, mastication, and other oral functions. Prosthodontic treatment for medically compromised patients is more difficult as compared with physically healthy patients. Either removable or fixed dentures are used according to the location and number of teeth to be recovered, as well as periodontal condition of the abutments. Among the prosthodontic appliances, resin-bonded fixed partial dentures (RB-FPDs) with minimal tooth reduction are applicable and acceptable as an option for the replacement of missing teeth adjacent to abutments with sufficient coronal tooth structure.

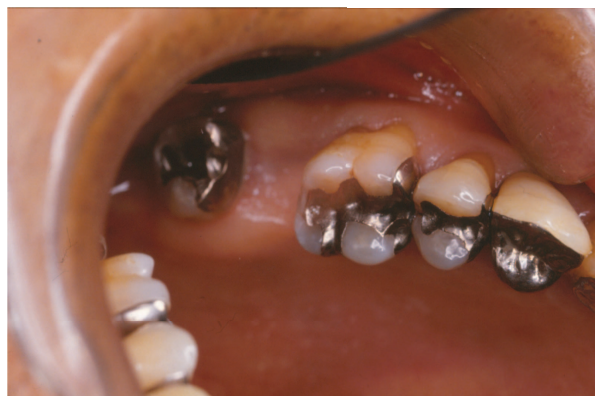Silver-palladium-copper-gold alloys are used extensively in Japan in fabrication of denture frameworks. In addition, single liquid primers that contain a thione monomer have been introduced for bonding dental noble metal alloys.<sup>1-11</sup> Although a number of prosthodontic applications of metal priming materials and luting agents have been reported,<sup>2-11</sup> only limited information is available concerning the long-term clinical performance of metal bonding systems.<sup>6,9</sup> This article describes the 6-year clinical performance of a RB-FPD applied to a diabetic one year after extraction of a second molar.

### Clinical Report

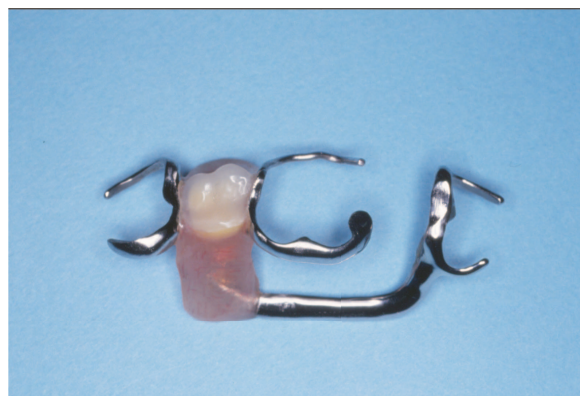A 60-year-old male patient presented with functional disturbances as a result of a missing maxillary right second molar. The patient was a diabetic, and had undergone extraction of second molar due to periodontitis (Fig. 1). Several treatment options were therefore proposed: 1) single-tooth implant, which is generally a contraindication for diabetics; 2) a removable partial denture (RPD); 3) FPD with considerable tooth reduction; and 4) RB-FPD after application of a transitional RPD. The patient chose the fourth of the proposed options. The prosthodontic procedure was then explained in detail and consent was obtained from the patient.

A removable partial denture was fabricated as a transitional prosthesis (Figs. 2-4). A buccal retentive arm for the first molar was made of Co-Cr alloy wire 0.9 mm in diameter. A metal framework with three clasps and a palatal bar was made of a Co-Cr casting alloy. The wire clasp and the cast framework were soldered. A composite resin tooth (Endura, Shofu Inc., Kyoto Japan) was arranged in the missing area. The denture was

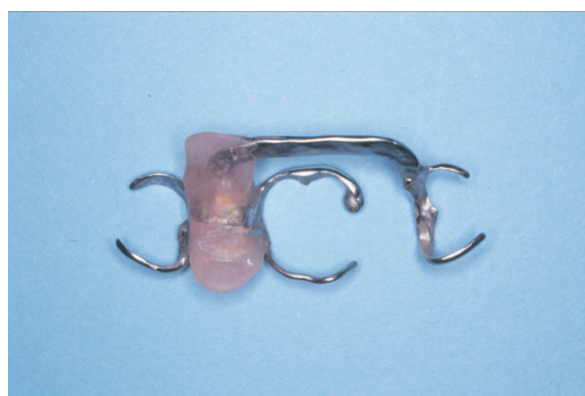
used for about one year during the periodontal therapy.



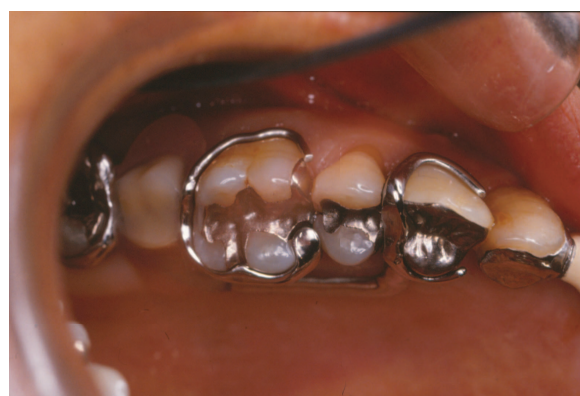**Fig. 1.** Maxillary second molar is missing.



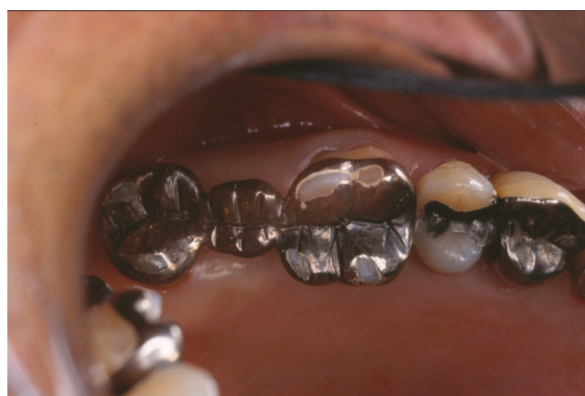**Fig. 2.** A removable denture with three clasps.



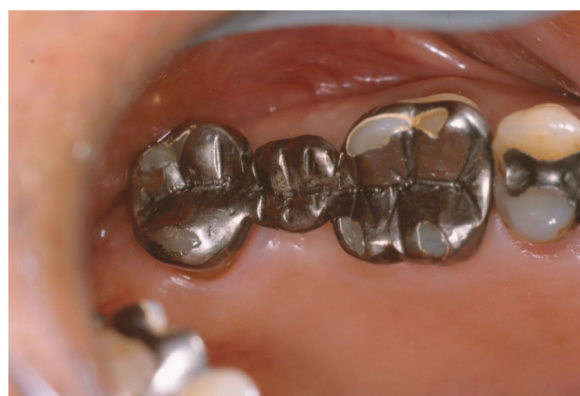**Fig. 3.** Metal framework structure.



**Fig. 4.** Seated removable partial denture.



**Fig. 5.** Resin-bonded fixed partial denture.



**Fig. 6.** Six years and six months after bonding.

For the second step, fabrication of a fixed partial denture was planned. This was due to improvement in the condition of the periodontal tissues of abutments, as well as a request for a fixed prosthesis by the patient. Intercuspal position and lateral mandibular movement were examined intraorally with articulating paper and extraorally using a stone cast. After examination of the maxillo-mandibular relation, the areas to be reduced were determined. Reduction of cusps was judged as unnecessary. However, inlay restorations of both first and third molars were removed and a base material was placed. An FPD consisting of two retainers and a flat back pontic was cast from a silver-palladium-copper-gold alloy (Castwell M.C. 12, GC Corp., Tokyo, Japan).

The completed FPD was tried-in at the next appointment. The inner surfaces of the retainers were air-abraded with 50- to 70- $\mu$ m grain sized alumina (Hi-Aluminas, Shofu Inc., Kyoto, Japan) using an airborne particle

abrader (Micro Blaster MB102, Comco Inc., Burbank, CA, USA), and treated with a single liquid primer designed for noble metal alloys (V-Primer, Sun Medical Co., Ltd., Moriyama Japan). The abutment enamel surfaces were etched with 40% phosphoric acid gel (K-Etchant, Kuraray Co., Ltd., Osaka, Japan), washed with water, and air-dried. The FPD was then seated with a tri-*n*-butylborane (TBB) initiated adhesive resin (Super Bond Opaque, Sun Medical Co., Ltd.). The patient then entered a maintenance program (Fig. 5). After an observation period of six years and six months, the RB-FPD was still functioning satisfactorily (Fig. 6).

## Discussion

One of the problems associated with prosthodontic treatment for diabetics is unpredictable prognosis of periodontal diseases around abutment teeth. Due to chronic marginal periodontitis of maxillary dentition, mobility of molars was moderate for this patient. The dentist in charge of the patient proposed options for prosthodontic treatments, and the patient accepted the two-stage procedure, i.e., seating a conventional RPD followed by seating a RB-FPD. A removable partial denture was fabricated for use as a transitional prosthesis. The denture was equipped with a combination clasp and two cast clasps. The cast clasp was placed around the first premolar and a cast palatal bar was additionally designed for convenience of removal-insertion of the denture, since the physical condition of the patient was not ideal. A combination clasp was placed around the first molar. This was due to convenience of control of retentive characteristics of the buccal wire arm. The patient was satisfied with the recovery of his oral function using the transitional RPD. In addition, treatment of periodontitis in the maxillary molar area was performed successfully.

One year after seating the RPD, condition of periodontal tissue around the first and third molar improved considerably. The patient requested change to a RB-FPD from the RPD, which was somewhat bulky and detachable during functioning. A RB-FPD was fabricated as the second step. Unfortunately, the first molar abutment moved slightly from its original position to the lingual side during fabrication of the FPD. The completed RB-FPD did not fit perfectly at the tri-in procedure. The dentist cemented the FPD temporarily with a soft-type polycarboxylate cement. After several weeks, adaptation to the abutments of the RB-FPD was judged as acceptable. The RB-FPD was seated with the technique described in the previous section.

One of the advantages of RB-FPD is that the reduction of intact enamel can be minimized. It is beneficial for medically compromised patients to apply a RB-FPD rather than a conventional FPD, which requires considerable reduction of sound tooth structure. Clinicians, however, should note that the prognosis of RB-FPDs applied to mobile abutments is not as good as that of conventional FPDs.

## Acknowledgments

This clinical report associated with adhesive bonding of dental casting alloys is supported in part by Grant-in-Aid for Scientific Research C 20592302 (2008) from the Japan Society for the Promotion of Science (JSPS), and a Grant from Dental Research Center (A), Nihon University School of Dentistry (2008).

## References

1. Atsuta M, Matsumura H, Tanaka T. Bonding fixed prosthodontic composite resin and precious metal alloys with the use of a vinyl-thiol primer and an adhesive opaque resin. *J Prosthet Dent* 1992; 67: 296-300.
2. Matsumura H, Atsuta M. Repair of an eight-unit fixed partial denture with a resin-bonded overcasting: A clinical report. *J Prosthet Dent* 1996; 75: 594-6.
3. Monya Y, Matsumura H, Atsuta M. A two-stage resin-bonded fixed partial denture seated in conjunction with postextraction healing of the alveolar socket: a clinical report. *J Prosthet Dent* 1998; 80: 4-8.
4. Shimizu H, Takahashi Y. Fixed splinting device to be used without removing adjacent existing cast restorations. *J Prosthet Dent* 1999; 82: 231-2.
5. Shimizu H, Habu T, Yanagida H. Stabilization by splinting of an endodontically treated premolar and a minimally reduced vital canine with a resin-bonded cast retainer: A clinical report. *Int Chin J Dent* 2002; 2: 121-5.

6. Hikage S, Hirose Y, Sawada N, Endo K, Ohno H. Clinical longevity of resin-bonded bridges bonded using a vinyl-thiol primer. *J Oral Rehabil* 2003; 30: 1022-9.
7. Tanoue N, Yanagida H, Matsumura H. Use of resin-bonded fixed partial dentures as permanent retainers: A clinical report. *Int Chin J Dent* 2004; 4: 40-3.
8. Tanoue N, Shimoe S, Nemoto M, Matsumura H. Repair and re-seating of resin-bonded fixed partial denture performed after minimal abutment reduction: A clinical report. *Int Chin J Dent* 2005; 5: 97-100.
9. Tanoue N, Ide T, Kawasaki K, Nagano K, Tanaka T. Survival of resin-bonded fixed partial dentures made from a silver-palladium-copper-gold alloy. *Int Chin J Dent* 2006; 6: 53-9.
10. Shimizu H, Takahashi Y, McKinney T. Resin-bonded castings with a cingulum rest seat and a guide plane for a removable partial denture: a case report. *Quintessence Int* 2008; 39: e11-4.
11. Shimizu H, Takahashi Y. Resin-bonded overcasting to salvage a long-span fixed prosthesis: a clinical report. *J Prosthodont* 2008; 17: 420-2.

**Correspondence to:**

Dr. Hiroyasu Koizumi  
Department of Fixed Prosthodontics, Nihon University School of Dentistry  
1-8-13 Kanda-Surugadai, Chiyoda-ku, Tokyo 101-8310, Japan  
Fax: +81-3-3219-8351 E-mail: koizumi@dent.nihon-u.ac.jp

Received February 10, 2009. Accepted March 30, 2009.  
Copyright ©2009 by the *International Chinese Journal of Dentistry*.