

Cast rest joint used as a movable connector between single restoration and adjacent pontic

Atsushi Mikami, DDS,^a Hiroyasu Koizumi, DDS, PhD,^{a,b} Yumi Ishikawa, DDS, PhD,^a Naomi Tanoue, DDS, PhD,^c and Hideo Matsumura, DDS, PhD^{a,b}

^aDepartment of Fixed Prosthodontics, and ^dDivision of Advanced Dental Treatment, Dental Research Center, Nihon University School of Dentistry, Tokyo, and ^cDepartment of Specialized Dentistry, Nagasaki University Hospital of Medicine and Dentistry, Nagasaki, Japan

This clinical report describes the application of a cast rest for movable connection between a pre-existing restoration and an adjacent pontic. A rest seat was prepared intraorally at the occluso-proximal marginal ridge of a premolar porcelain-fused-to-metal (PFM) restoration. A fixed partial denture (FPD) with a pontic and an extended cast rest was fabricated. Two different FPDs with rest seats were placed and clinically evaluated. After observation periods of one and four years respectively, both FPDs were functioning satisfactorily. Combination of a rest seat sunk into an intraoral restoration and a cast rest adjacent to a pontic can be applied as one of the options of semi-fixed partial dentures, if properly designed. (*Int Chin J Dent* 2007; 7: 65-68.)

Key Words: movable connector, non-rigid connector, semi-fixed partial denture, rest seat.

Introduction

Movable connectors are used in fixed prosthodontics for rehabilitation of cleft palate patients¹ as well as in resin-bonded fixed partial dentures (FPD).²⁻⁵ A key and keyway connector is a typical non-rigid attachment system^{6,7} frequently applied to tilted abutments and long-span fixed partial dentures especially for the connection between premolars and molars. An occlusal rest combined with a rest seat is a representative supporting medium of cast denture clasps. Although combination of a cast rest and rest seat is usually applied to removable partial dentures, it may also be possible to apply such a system to semi-fixed partial dentures. This clinical report presents two cases of non-rigid fixed partial dentures each having a pre-existing intraoral restoration and a cast rest as movable connector.

Clinical Report

A fixed partial denture seated after hemisection of a mandibular molar

A 56-year-old male patient presented with the chief complaint of dull pain and discomfort on chewing around the mandibular molar. Examination revealed fracture of the mesial root of the left mandibular molar. Among the treatment options, the patient preferred hemisection of the molar, i.e., extraction of mesial root, and seating of a short span fixed partial denture. During healing of the alveolar socket, the patient requested, if all at possible, not to remove the porcelain-fused-to-metal (PFM) restoration of the adjacent second premolar. Fabrication of a fixed partial denture with a premolar-shaped retainer, a narrow hygienic pontic, and a cast rest seat extending from the pontic was proposed, and the patient agreed to have the treatment.

A rest seat with one-third bucco-lingual width of the occlusal table and 1.5 mm depth was prepared with a diamond rotary instrument on the porcelain occlusal surface of the second premolar (Fig. 1). During the healing of the alveolar bone and periodontal tissues, a cast dowel core made of silver-palladium-copper-gold (Ag-Pd) alloy (Castwell M.C.12, GC Corp., Tokyo, Japan) was seated with the Super-Bond opaque resin (Sun Medical Co., Ltd., Moriyama, Japan). Before seating, the root canal dentin was treated with 10% citric acid 3% ferric chloride aqueous solution (Green Etchant, Sun Medical Co., Ltd.) for 30 s, whereas the dowel core, after try-in, was air-borne particle abraded with alumina, and a metal priming agent (Metaltite, Tokuyama Dental Corp.,

Tokyo, Japan) was applied. After abutment preparation, an impression was made with silicone elastomeric material, poured with die stone, and a working cast was prepared. A wax pattern of the FPD was prepared, invested into the mold material, and Ag-Pd alloy was cast in the mold using a centrifugal casting apparatus (Fig. 2). After adjustment and polishing, the FPD was seated on the molar abutment with a glass-ionomer luting material (Ketac-Cem RO, Espe, Seefeld, Germany) (Figs. 3 and 4). The luting agent was not applied to the movable connector. The patient entered into a maintenance program (Fig. 5). During a period of four years, no critical problems were observed in the functioning of the FPD.

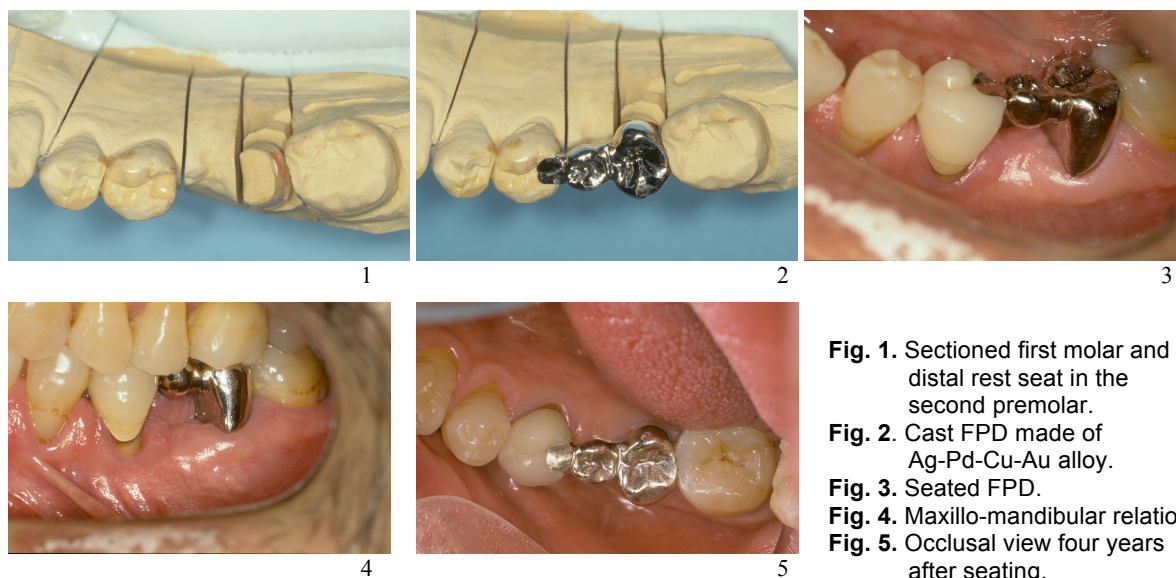


Fig. 1. Sectioned first molar and a distal rest seat in the second premolar.
Fig. 2. Cast FPD made of Ag-Pd-Cu-Au alloy.
Fig. 3. Seated FPD.
Fig. 4. Maxillo-mandibular relation.
Fig. 5. Occlusal view four years after seating.

A cantilever fixed partial denture with two pontics

A 60-year-old female patient presented with the chief complaint of masticatory dissatisfaction due to mobility of a molar. Radiographic examination revealed fracture of the left maxillary second molar. In addition, she had lost her second premolar several years ago (Fig. 6).

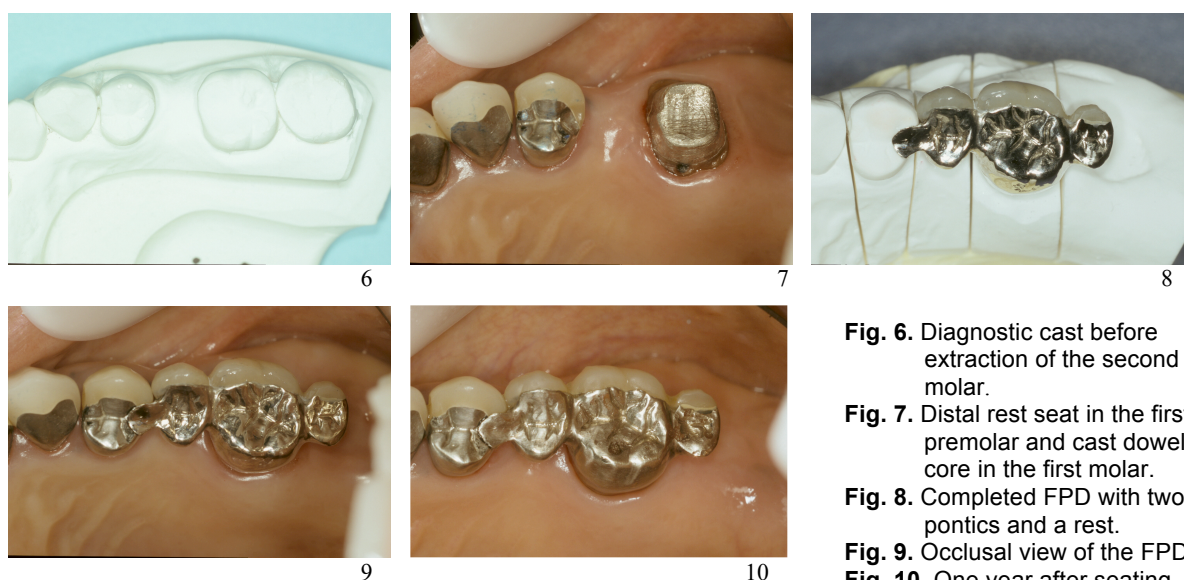


Fig. 6. Diagnostic cast before extraction of the second molar.
Fig. 7. Distal rest seat in the first premolar and cast dowel core in the first molar.
Fig. 8. Completed FPD with two pontics and a rest.
Fig. 9. Occlusal view of the FPD.
Fig. 10. One year after seating.

The fractured second molar was extracted and replacement of the missing teeth was planned. Treatment options including removable partial dentures were proposed, and the patient opted for seating a cantilever fixed

partial denture. The patient also strongly desired preservation of the adjacent premolar PFM restoration. The design of the FPD therefore consisted of a cantilever short pontic at the second molar region, veneered retainer for the first molar, and ridge lap pontic with a mesial rest for the premolar area.

The single restoration of the first molar was removed, recurrent dental caries removed, and a dowel core made of Ag-Pd alloy was bonded with the Metaltite primer and the Super-Bond resin. A rest seat was prepared in the occlusal table of the first premolar (Fig. 7). A cast framework of a three-unit cantilever FPD with mesial rest was fabricated with Ag-Pd alloy (20% Au, AP Ace 500P, Tokuriki Honten Co., Ltd., Tokyo, Japan). After the try-in process, the buccal surface was veneered with the Ceramage composite material (Shofu Inc., Kyoto, Japan) (Fig. 8). The FPD was then seated with a glass ionomer luting agent (Ketac-Cem μ Easy Mix, 3M Espe, St. Paul, MN, USA) (Fig. 9). The FPD is functioning for more than one year after seating (Fig. 10).

Discussion

A cast rest made of Ag-Pd alloy was placed on the occlusal table of the premolar restoration in the first patient. The patient did not feel any discomfort due to the outline form of the rest, pontic, and premolar-shaped molar retainer. There was gingival recession around the second premolar before placement of the FPD. However, the PFM restoration was not damaged during the treatment, except for preparation of a rest seat. As shown in Fig. 5, loss of gloss was detected on the surface of the rest. This was detected four years after seating the FPD, and resulted probably from repeated occlusal contact with the maxillary antagonist. The shiny appearance was recovered by polishing both the rest surface as well as the antagonist cusp using a rotary polishing instrument.

A special FPD was placed in the second case, without removing the premolar restoration, as per the patient's request. The cantilever pontic was placed to maintain occlusal contact between the mandibular second molar and the extended maxillary pontic. A cast rest was placed on the occlusal table of the first premolar. The rest made of Ag-Pd alloy was placed overlying the metal-ceramic joint. Such a joint should be avoided, if possible, because the two alloys have different composition, and intraoral contact of different alloys may induce corrosion of the metallic materials. Fortunately, no symptoms of accelerated corrosion were detected in this patient. This could probably be due to the high content of noble metal element in both the Ag-Pd alloy and the gold alloy for metal-ceramic restorations.

The authors believe that combination of a rest seat prepared on natural teeth and a cast rest should be avoided in a movable joint. This is due to the fact that it is difficult to remove plaque from the tooth surface under the movable joint, and the reduced enamel is susceptible to iatrogenic dental caries as compared with intact enamel.

Although removal of premolar restorations is a usual and proper approach in fixed prosthodontic practice, placement of FPDs with a movable joint is also one of the treatment options, considering varying conditions of each patient.

Acknowledgment

This clinical report associated with adhesive bonding and wear behavior of dental casting alloys is supported in part by Uemura Fund, Nihon University School of Dentistry (2005) and by Sato Fund, Nihon University School of Dentistry (2007).

References

1. Kelleher MG. A movable joint, composite attached bridge for a cleft palate patient. *Restorative Dent* 1984; 1: 27-8, 30-1.
2. Dummer PM, Gidden JR. Two-part resin bonded cast metal bridges for use when abutment teeth have unequal effective root surface areas. *Restorative Dent* 1990; 6(3): 9-14.
3. Pollock GR. Case report: the use of a resin retained bridge with movable joint. *Eur J Prosthodont Restor Dent* 1996; 4: 35-8.

4. Botelho MG. Improved design of long-span resin-bonded fixed partial dentures: three case reports. Quintessence Int 2003; 34: 167-71.
5. Botelho MG, Dyson JE. Long-span, fixed-movable, resin-bonded fixed partial dentures: a retrospective, preliminary clinical investigation. Int J Prosthodont 2005; 18: 371-6.
6. Moulding MB, Holland GA, Sulik WD. An alternative orientation of nonrigid connectors in fixed partial dentures. J Prosthet Dent 1992; 68: 236-8.
7. Appleby DC, Dietz AJ. A resin-bonded conversion attachment for the reversal of key/keyway position in a nonrigid connector. J Prosthet Dent 1993; 69: 121-2.

Correspondence to:

Dr. Hiroyasu Koizumi

Department of Fixed Prosthodontics, Nihon University School of Dentistry

1-8-13 Kanda-Surugadai, Chiyoda-ku, Tokyo 101-8310, Japan

Fax: +81-3-3219-8351 E-mail: koizumi@dent.nihon-u.ac.jp

Received July 31, 2007. September 1, 2007.

Copyright ©2007 by the *International Chinese Journal of Dentistry*.