

Zygoma fixtures for a patient with a severely atrophic maxilla: A clinical report

Ikuya Watanabe, DDS, PhD,^a Sloan Hildebrand, DDS, MS,^b Ronald D. Woody, DDS, MS,^b and Reena Talwar, DDS, PhD^c

^aDepartment of Biomaterials Science, ^bGraduate Prosthodontics, and ^cDepartment of Oral & Maxillofacial Surgery/Pharmacology, Baylor College of Dentistry, Texas A&M University System Health Science Center, Dallas, TX, USA

This clinical report describes a functional and esthetic reconstruction using Brånemark zygoma fixtures for a patient with severely atrophic maxilla and Sjögren's syndrome. After the extraction of the anterior maxillary teeth, two zygoma fixtures and four Brånemark implants were placed in the patient's maxilla. Five Brånemark implants were also placed in the mandible at the same time. After the implant placement, the maxillary and mandibular implants were restored with fixed detachable dentures. These functional and esthetic prostheses have performed favorably without any problems for one year. (*Int Chin J Dent* 2005; 5: 71-74.)

Key Words: esthetics, fixed detachable denture, function, zygoma fixture.

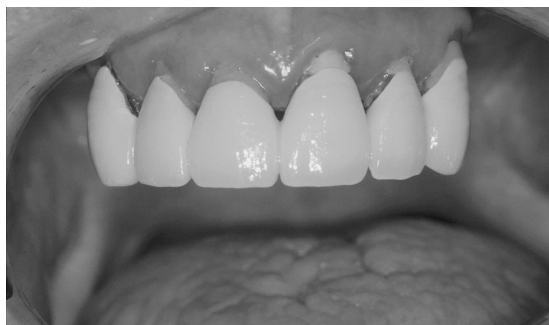Introduction

Osseointegrated implants have supported craniofacial prostheses after the introduction of these implants in the 1980s. Longer custom-designed implants inserted into the zygomatic bone combined with the standardized Brånemark system were introduced to treat patients with advanced atrophy of the maxilla.¹⁻⁴ The zygoma transsinus fixture was designed to be anchored apically in the zygomatic bone and marginally on the palatal side of a minimal residual alveolar crestal bone. Using this technique, bone grafts could be minimized or avoided altogether, and adequate mechanical stability could be achieved as well as providing greater posterior support. To obtain the long-term stability of a maxillary full arch implant-supported restoration, the manufacturer recommends rigid connection of two zygoma fixtures (one on each side) with at least two stable conventional Brånemark system fixtures in the anterior maxilla. Using zygoma fixtures also reduces morbidity, especially in elderly patients with compromised general health for whom bone grafting could be hazardous. Compared with the traditional rehabilitation with bone grafts, the total treatment time can be shortened using the zygoma implants. This clinical report describes the functional and esthetic reconstruction using Brånemark zygoma fixtures for a patient with a severely atrophic maxilla and Sjögren's syndrome.

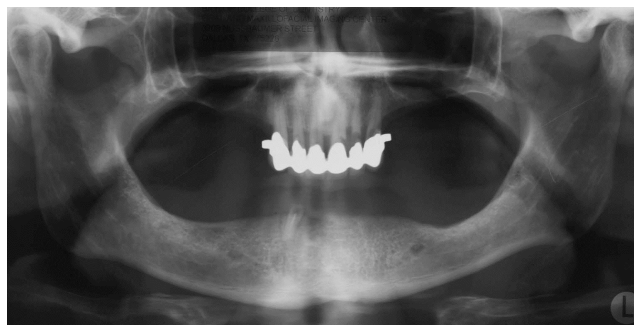Clinical Report

The 70-year-old male patient in this report had an edentulous mandible with a root tip canine and failing restoration (patchwork composite resin at the margins) of an anterior maxillary fixed partial denture (Fig. 1). Due to the diminished salivary flow caused by Sjögren's syndrome, the patient's tongue and mucosa appeared dry and red. Radiographic evaluation showed that the maxillary sinus floor appeared to be pneumatized in the right/left posterior areas (Fig. 2), and there was generalized bone loss throughout the mandible and severe maxillary bone loss. Several possible treatment options, including extraction of the remaining dentition and restoration with complete dentures, implant-supported dentures with sinus lift and bony augmentation, and implant-supported dentures with bilateral zygomatic implants, were outlined to the patient. The definitive plan

that the patient accepted was the placement of maxillary/mandibular implant-supported fixed detachable dentures with bilateral zygomatic implants.




1



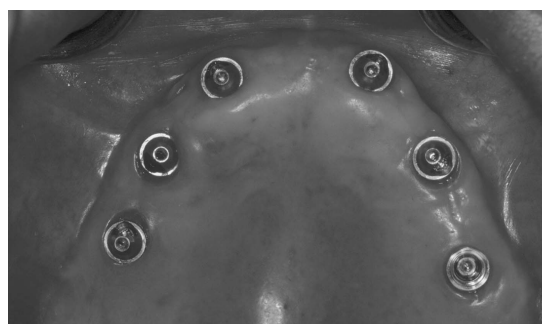
2

Fig. 1. Frontal view of the patient referred for prosthetic evaluation.

Fig. 2. Preoperative panoramic radiograph of the patient.



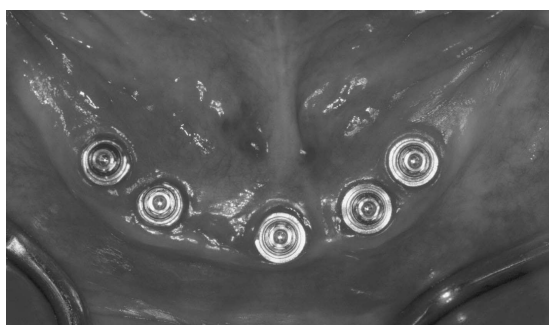3



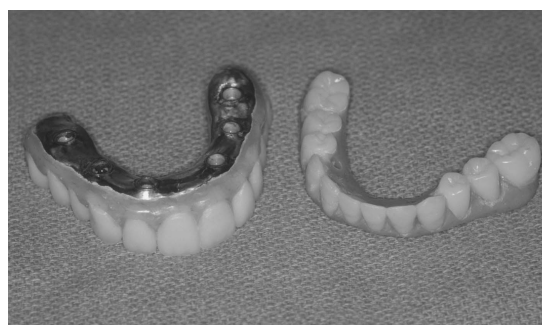4

Fig. 3. Delivery of zygoma fixture. Arrow indicates the window on the lateral wall of the sinus close to the infrazygomatic crest.

Fig. 4. Implant abutments in maxilla. Note the dry mucosa.



5

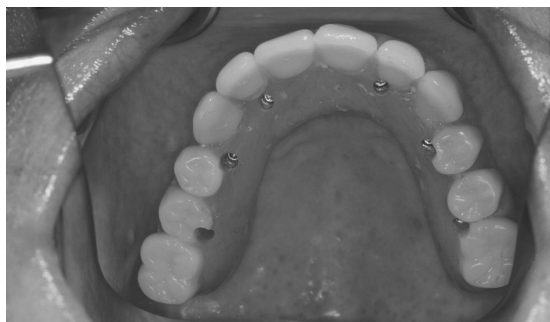

6

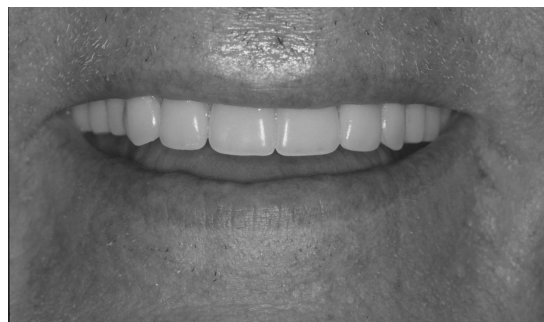
Fig. 5. Implant abutments in mandible. All standard multiunit abutments.

Fig. 6. Fixed detachable prostheses for maxilla (left) and mandible (right).

Before the surgery for the implant placement took place, surgical guides were fabricated on the master cast mounted on a semi-adjustable articulator. After the anterior teeth were extracted, two Brånemark zygoma fixtures (right: 42.5 mm; left: 50 mm) were placed in the second premolar area of the maxilla according to standard clinical procedures (Fig. 3).³ Conventional Brånemark implants (Mk III Tiunite, RP Ø4 x 13 mm; RP Ø4 x 15 mm, Nobel Biocare USA Inc., Yorba Linda, CA, USA) were also placed in the maxilla (Fig. 4, four implants) and the mandible (Fig. 5, five implants). The patient's existing dentures relined with soft liner material (relined every 3-4 weeks) were used to maintain the proper vertical dimension during the interim stages of surgery.



7



8

Fig. 7. Maxillary fixed detachable denture at delivery.

Fig. 8. Extraoral view of the patient after restoration.

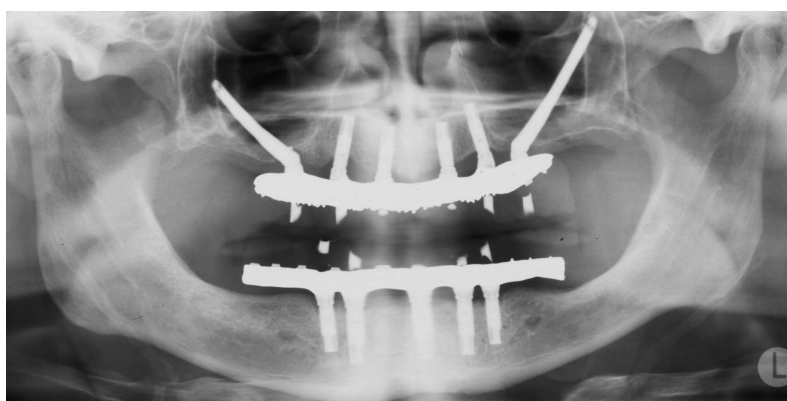

Fig. 9.
Postoperative panoramic
radiograph of the patient.

Three months after this surgery, secondary surgery was conducted to place all healing abutments. Final impressions were then taken for the definitive maxillary and mandibular prostheses. The metal frameworks for the implant-supported superstructure were fabricated with cast gold alloy (Ney-Oro 60, Degussa-Ney Inc., Bloomfield, CT, USA) and gold cylinders (BI-00035, OD Ø4.8, Nobel Biocare USA, Inc.). After the passive fit of the cast metal frameworks and wax dentures were verified intraorally, final fixed detachable dentures were fabricated according to conventional methods (Fig. 6). The definitive fixed detachable prostheses were finally torqued to 20 Ncm with gold retaining screws in the patient's mouth (Fig. 7). The definitive prostheses provided a group function occlusal scheme. The patient was satisfied with these functional and esthetic prostheses (Fig. 8), which have performed favorably for one year without any visible radiographic bone resorption (Fig. 9).

Discussion

Bone grafts must sometimes be performed before implant placement because of insufficient bone volume and bone loss (resorption) in order to establish functional and esthetic maxillary and mandibular restorations. In the present clinical case, zygoma fixtures were used to help restore a patient with a severely atrophic maxilla. The use of zygoma fixtures reduces the preoperative risks compared with traditional surgical methods including bone grafts, which suggests that elderly patients with increased general health-related problems can be rehabilitated properly. Compared to the overall fixture survival rate in conventional bone grafting, it seems that the zygoma fixture has a higher survival rate. The survival rate for grafted patients varies from 60-87% according to reports for follow-up periods from 19 months to 15 years.⁵⁻¹⁰ On the other hand, Hirsch et al.⁴ evaluated the survival rate of 124 zygoma fixtures in 76 patients at 16 clinics and reported that the overall survival rate for zygoma fixtures was 97.9% after a 1-year follow-up. The present clinical case is similar to their study because the patient was recalled for a 1-year

check-up. Brånemark et al.³ also reported an overall survival rate of zygoma fixtures of 94% after a longer follow-up period of five to 10 years for 52 fixtures in 28 patients. The main advantage of zygoma fixtures over conventional bone grafting is the reduction in treatment time. A further advantage is that the number of implants required to support a fixed prosthesis could be reduced. However, a potential disadvantage to consider with zygoma fixtures is the risk of orbital injury or postoperative sinusitis.² Although no orbital injury or complications occurred in the present case, follow-up appointments to monitor the zygoma fixtures and prostheses' function will continue.

Acknowledgment

Editorial assistance by Mrs. Jeanne Santa Cruz is appreciated.

References

1. Worthington PH, Brånemark PI. Advanced osseointegration surgery. Chicago: Quintessence Publishing Co; 1992. p. 15.
2. Higuchi KW. The zygomaticus fixture: an alternative approach for implant anchorage in the posterior maxilla. *Ann R Australas Coll Dent Surg* 2000; 15: 28-33.
3. Brånemark PI, Gröndahl K, Öhrnell LO, et al. Zygoma fixture in the management of advanced atrophy of the maxilla: technique and long-term results. *Scand J Plast Reconstr Hand Surg* 2004; 38: 70-85.
4. Hirsch JM, Öhrnell LO, Henry PJ, et al. A clinical evaluation of the zygoma fixture: one year of follow-up at 16 clinics. *J Oral Maxillofac Surg* 2004; 62 (Suppl 2): 22-9.
5. Isaksson S. Evaluation of three grafting techniques for severely resorbed maxillae in conjunction with immediate endosseous implants. *Int J Oral Maxillofac Implants* 1994; 9: 679-88.
6. Lundgren S, Nyström E, Nilsson H, Gunne J, Lindhagen O. Bone grafting to the maxillary sinuses, nasal floor and anterior maxilla in the atrophic edentulous maxilla. A two-stage technique. *Int J Oral Maxillofac Surg* 1997; 26: 428-34.
7. Lekholm U, Wannfors K, Isaksson S, Adielsson B. Oral implants in combination with bone grafts. A 3-year retrospective multi-center study using the Brånemark implant system. *Int J Oral Maxillofac Surg* 1999; 28: 181-7.
8. Keller EE, Tolman DE, Eckert SE. Maxillary antral-nasal inlay autogenous bone graft reconstruction of compromised maxillae: a 12-year retrospective study. *Int J Oral Maxillofac Surg* 1999; 14: 707-21.
9. Kahnberg KE, Nilsson P, Rasmusson L. Le Fort I osteotomy with interpositional bone grafts and implants for rehabilitation of the severely resorbed maxilla. A 2-stage procedure. *Int J Oral Maxillofac Implants* 1999; 14: 571-8.
10. Brånemark PI, Gröndahl K, Worthington P. Osseointegration and autogenous onlay bone grafts: reconstruction of the edentulous atrophic maxilla. Chicago: Quintessence Publishing Co.; 2001. p. 6.

Reprint request to:

Dr. Ikuya Watanabe
Department of Biomaterials Science, Baylor College of Dentistry
Texas A&M University System Health Science Center
3302 Gaston Ave., Dallas, TX 75246, USA
Fax: +1-214-370-7001 E-mail: iwatanabe@bcd.tamhsc.edu

Received August 5, 2005. Revised August 15, 2005. Accepted August 23, 2005.

Copyright ©2005 by the Editorial Council of the *International Chinese Journal of Dentistry*.