

## Expression of telomerase and p53 in ameloblastoma of the jaw

Ming Zhong, DDS, MS,<sup>a</sup> Luhuang Zhang, DDS, MD,<sup>a</sup> Jie Wang, DDS, MD,<sup>a</sup> Bo Zhang, DDS, PhD,<sup>b</sup> and Lin Hou, DDS<sup>b</sup>

<sup>a</sup>Department of Pathology, College of Stomatology, China Medical University, Shenyang, and

<sup>b</sup>Department of Pathology, Medical College, Peking University, Beijing, P. R. China

**Purpose:** This study was aimed to detect the expression of p53 protein, hTR, and hTERT (telomerase reverse transcriptase, TERT) mRNA in ameloblastoma (AB) of the jaw, and to investigate its correlation with the clinical and biological features of AB.

**Materials and Methods:** In situ hybridization and immunohistochemical assay were used to detect the expression of HTR and hTERT mRNA in 54 cases of AB. Meanwhile, S-P method was used to determine the expression of p53 protein in 49 cases of ABs. Specimens from 25 cases of odontogenic keratocyst (OKC) and seven cases of normal oral mucosa were used as control. Chi square test and Kendall Pearson correlation analysis were used to determine the relationship between gene expression and clinical features of AB.

**Results:** The positive ratio of hTR, hTERT mRNA was 2/7 and 1/7 in normal oral mucosa, respectively; 81.2% (13/16) and 87.4% (14/16) in odontogenic keratocyst (OKC), 94.4% (51/54) and 94.4% (51/54) in AB, respectively. There were significant differences among these three groups ( $p < 0.001$ ). The hTR was strongly correlated with hTERT mRNA ( $rs = 1.000$ ,  $p < 0.001$ ). The p53 protein was expressed in nucleolus of 87.5% (42/49) AB, 44% (11/25) OKC, 33.3% (1/3) normal oral mucosa, respectively. A strong correlation between hTERT mRNA and p53 protein was found ( $rs = 0.754$ ,  $p < 0.001$ ). An intermediate positive correlation between hTR mRNA and p53 protein was noted ( $rs = 0.536$ ,  $p < 0.001$ ).

**Conclusion:** The positive ratios of hTR and hTERT were significantly higher than p53 protein in AB. Telomerase activity and p53 expression play an important role in genesis and development of AB.

(Int Chin J Dent 2004; 4: 27-33.)

**Clinical Significance:** The study investigated that the high expression of hTR and hTERT was closely related to the clinical biological behavior of AB and regulated by p53 protein, which provided a significant proof for looking for a new target to therapy AB by gene.

**Key Words:** ameloblastoma, hTERT, hTR, odontogenic keratocyst, p53 protein, telomerase.

### Introduction

The activated telomerase was first found in human cervical cancer cells by Morin in 1989. In 1994, Kim et al.<sup>1</sup> described the highly sensitive telomerase repeat amplification procedure (TRAP) based on PCR for the first time, which enables the detection of the activity of telomerase. Currently TRAP was extensively applied in studies of various tumors and carcinogenesis. The expression of the activity of telomerase involves a complex mechanism and regulated by multitudinous factors. However, the expression of hTR, hTERT and p53 protein, and their relations in ameloblastoma (AB) and odontogenic keratocyst (OKC) of the jaw were not clear until now. This study was aimed to detect the expression of p53 protein, hTR, and hTERT mRNA in ameloblastoma (AB) of the jaw, and to investigate its correlation with the clinical biological characteristics of AB.

## Materials and Methods

### Tissue Specimens

The tissue specimens were filed paraffin-embedded from the Pathological Department of the First Affiliated Clinical College of China Medical University between the year of 1996 and 2000, which included 54 ameloblastomas of the jaw. Among them, 31 were primary, 19 were recurrent, and four were with malignant transformation. There were 25 males and 29 females, their age ranged from nine to 69 years with an average of 33.4 years. Thirty-three tumors involved the mandibular molar region and ascending ramus (61.1%). The time to recurrence was from two months to 26 years with an average of 6.7 years. Several patients even had four times of recurrence. Twenty-five cases with odontogenic keratocyst (OKC) and seven cases of normal oral mucosa were used as control.

All the specimens were fixed in 10% formaldehyde and routinely paraffin-embedded 3-ammopropyl-triaecoxysilicone (APES) was smeared for slass retention. The sections were 4  $\mu$ m thick. Thirty sections were obtained in each case and three were randomly selected for experiment. The sections were spread with double distilled water containing 0.1% diethyl oxydifomate (DEPC). All the specimens were subjected to detection of hTR, hTERT and p53 protein, although the cases were not exactly the same due to staining problems.

### Main Reagents

MAB of p53, S-P supersensitivity assay and DAB ingrain agent were products from Maxim, and p53 mRNA probes were purchased from the Department of Pathology, Medical College, Peking University. The plasmid containing hTR gene (pGR) was a present from Dr. Geron. The bacterium was conventionally transformed and the plasmid amplified. The restricted incision enzyme Mlu I was used for linearization of the plasmid, then the hTR cRNA probes were prepared utilizing ex vivo transcription. According to the hTERT mRNA sequence reported by Nakamura et al., a pair of primer was designed both in the up and down stream of the open reading frame with a length of 626 bp. To facilitate the subsequent cloning of the PCR products, Sal I and Bamh I enzyme cutting situs were imported at 5' end of the two primers with preservation of four additional basic groups, to warrantee the effective cutting by the restricted incision enzymes. The primers were synthesized by Shanghai Sai Bai Sheng (SBS) Company with the sequence as follows: 5'-TATAGTCGACGT GGAAGATGAGCGTGCGG3'; 3'-primer 5'ACACGGATC CACCTTGACAAAGTACAGCTC3'. Orentational cloning was adopted with Sal I and Bamh I cutting the PCR products and pBLuescript SK+vector. The sub products were retrieved and purified, processing according to the proposed steps of T<sub>4</sub> ligase by Gibco-BRL Co., coupled reaction at 26°C to 28°C for two hours, then the coupled mixture was used for transforming Escherichia coli JM109 strain, with the latter spreading on the agar plate containing Ampicillin, cultured at 37°C overnight. Individual colony was chosen for further culture, and the plasmid DNA was prepared with basic fragmentation. Sal I and Bamh I were used for cutting and probation. The positive clone was filtrated, and the plasmid was linearized with incision enzymes. Ex vivo transcription was used to prepare biotin hTERT cDNA probes.

### Immunohistochemical Assay

According to the specifications of the reagent made by Fuzhou Maixin company, Fujian, P. R. China, cases of breast cancer were used as positive control, while PBS substituted the first antibody as negative control.

### In Situ Hybridization

The paraffin-embedded blocks were routinely sectioned and dewaxed. After hydration with alcohol, the sections were treated with chlorhydric acid (0.1mol/L), digested with protease K (1:100) at 37°C for 15 minutes, then fixed with 4% paraformaldehyde at -20°C for 10 minutes, dehydrated with 90% icy alcohol for one to two minutes, placed in wet boxes containing 50% formamide, dropwising 20 µL hybridism liquid (containing 50% formamide, ssDNA 2 µL, probe 2 µL, 50 mmol/L DTT, 5xDenharts, 5% dextron sulfate, 4xSSC) in each section. The sections were sealed with sealing films, and the wet boxes were placed in the warm closets at 37°C for 20 hours. After hybridization, the sections were rinsed with 50% formamide, 2xSSC containing 50% formamide at 37°C for 30 minutex1, rinsed with 2xSSC at 42°C for 15 minutesx3, 0.1xSSC at 37°C for 15 minutesx1, Buffer I (100 mmol/L Tris-cl pH>0.5, 150 mmol/L NaCl) for 5 sx1. Sera equinum (1:100) was added, sealed at room temperature for 40 minutes. Anti-Dig-AP (1:500) was added and sealed at room temperature for another 60 minutes, stained with NBT/BCIP for 30 minutes, sealed with gelatin. Oral squamous cell carcinoma was served as positive control; sections without addition of probes were as negative control.

### Outcome Evaluation

Positive p53 protein was brown-yellow particles in the nucleus. Each section was observed and determined under low power lens (40x, 100x), then the positive nuclei were counted under high power lens (200x). Double blind was adopted in counting and the average values were calculated from three fields of vision. Positive hTR and hTERT was considered when purple-blue particles present in the cytoplasm. Less than 10% was (-), 10% to 40% was (+), 40% to 70% was (++), and more than 70% was (+++).

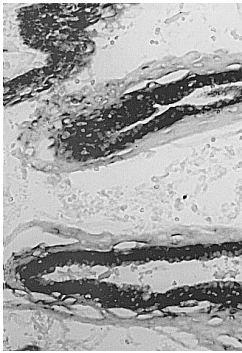
### Statistical analysis

SPSS 10.0 software was used for chi square test and Kendall Pearson correlation analysis. P<0.05 was considered to be significantly different.

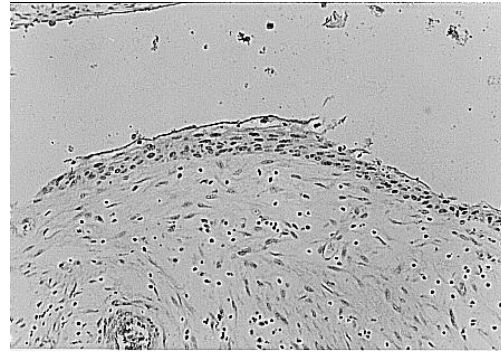
## Results

In the normal oral mucosa, hTR and hTERT were weakly positive in the basal layer of the epithelium in 2/7 and 1/3 specimens, respectively. The p53 protein was lightly positive in the nucleus of the basal cells in one section. The expression rate of hTR and hTERT in OKC was 81.3% (13/16) and 87.5% (14/16), respectively, from the basal layer to the accessory basal layer, mainly weakly positive and intermediately positive. The expression of hTR and hTERT in keratinocytes was negative (Fig. 1). The p53 protein was negatively stained in 14 OKCs, while in 11 OKCs, the nucleuses of the basal cells were positively stained (Fig. 2) but weak. HTR and hTERT was positively expressed in 51 of 54 Abs (94.4%), dominated by intermediate and strong staining. The stain was mostly distributed in the peripheral column cells or cube

cells as well as the scattered or densely proliferated polygon cells and spindle cells. The keratinized degeneration-shape cells and granular cells were not stained (Fig. 3). Most of the matrix had no signals of hTR and hTERT mRNA, except some inflammatory cells. In areas of fibrocyte densely proliferating or active, signals of hTR and hTERT were noted in two and six cases, respectively. The p53 positive protein was mainly distributed in the nucleuses of the peripheral and stellate cells of ameloblastoma, in particular, in the zones with extensive cell proliferation. Similarly, the keratinized degeneration-shape cells and granular cells were seldom or not stained (Fig. 4). In contrast, p53 mRNA was positive in the cytoplasm of granular cells, weakly positive in most ABs and intermediately positive in fewer ABs. In 13/49 (26.5%) cases, p53 protein was negative while hTR and hTERT was positive.



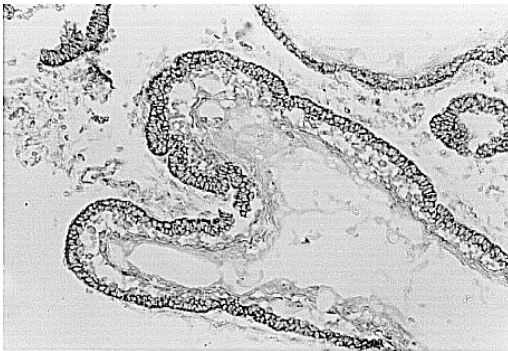
1



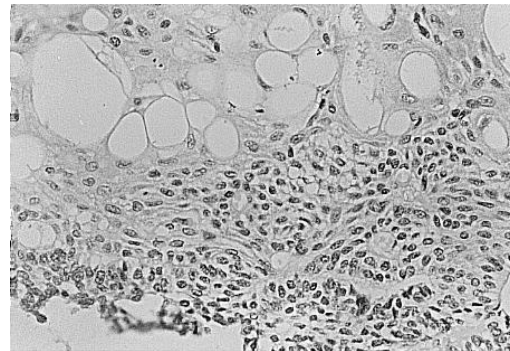
2

**Fig. 1.** The hTR mRNA was strongly positive in basal cells and negative in keratinocyte in OKC (in situ hybridization, x400).

**Fig. 2.** The p53 protein was positive in cell nucleus of OKC (S-P method, x160).



3



4

**Fig. 3.** The hTERT mRNA was strongly positive in peripheral cells and negative in keratinized degeneration-shape cells of AB (in situ hybridization, x160).

**Fig. 4.** The p53 protein was positive in peripheral and proliferative stellate central cells, negative or lightly positive in keratinized degeneration-shape cells of AB (S-P method, x200).

Clinicobiologically, in 31 cases with primary AB, the positive rate of hTR and hTERT was 96.7% (30/31) and 93.5% (29/31), respectively; while in 19 cases with recurrent AB, the positive rate of hTR and hTERT was 89.4% (17/19) and 94.9% (18/19), respectively. In four cases with malignant AB, the positive rate was 100% (4/4). The positive rate and intensity of hTERT mRNA raised with recurrence of AB and the increased grades of malignancy, while there was no significant relation in hTR between primary cases

and recurrent cases, except significant differences between primary cases and malignant cases, recurrent cases and malignant cases ( $p < 0.05$ ), which was detailed in Table 1. Similarly, in cases with recurrent and malignant ABs, p53 protein was significantly increased, compared with primary ABs, ( $p < 0.01$ , Table 2).

**Table 1.** Relationship between the expression of hTR and hTERT mRNA, and clinical biological behavior of AB.

Groups	No.	hTR mRNA				hTERT mRNA			
		-	+	++	+++	-	+	++	+++
Primary	31	1	2	19	9	2	6	13	10
Recurrent	19	2	0	3	14	1	2	2	14
Malignant	4	0	0	1	3	0	0	0	4

Note: hTR  $\chi^2=14.419$ ,  $p < 0.025$ ;  $\chi^2=12.921$ ,  $p=0.005$  between primary and recurrent AB. hTERT  $\chi^2=8.687$ ,  $p < 0.05$  between primary and recurrent AB.

**Table 2.** The expression of p53 protein with clinical grades of AB.

Groups	No.	X (SD)	P value
Primary	22	13.7 (5.6)	F=95.717
Recurrent	24	52.2 (20.1)	$p < 0.001$
Malignant	3	368.3 (31.0)	

Note:  $p < 0.01$  between primary AB and recurrent AB, primary AB and malignant AB, recurrent AB and malignant AB.

**Table 3.** The correlation of the expression of hTR and hTERT in AB.

hTR	hTERT			
	-	+	++	+++
-	7	3	1	0
+	0	3	2	1
++	3	4	11	10
+++	1	2	9	20

Note: Kendall correlation analysis,  $r_s=1.000$ ,  $p=0.001$ .

**Table 4.** The expression of hTR, hTERT mRNA and p53 protein in AB, OKC and normal oral mucosa.

	No.	hTR mRNA				hTERT mRNA				P53 (x200) X
		-	+	++	+++	-	+	++	+++	
Oral mucosa	7	71.4	0	28.6	0	85.7	14.3	0	0	1.4000
OKC	16	18.8	25	18.8	37.5	12.5	18.8	50	18.8	2.0800
Primary AB	31	3.2	6.5	61.3	29.0	31	6.5	19.4	41.9	13.7136
Recurrent AB	19	10.5	0	15.8	73.7	5.3	10.5	10.5	73.7	52.2083
Malignant AB	4	0	0	25.0	75.0	0	0	0	100	368.3333

In addition, the expression of hTR, hTERT mRNA and p53 protein in AB was not correlated to the primary sites, X-ray features (monolocular or multilocular) and histopathologic patterns (follicular, plexiform, granule cell subtype and desmoplastic) ( $p > 0.05$ ).

Clinicopathologically, several follicular tumors underwent granular cell transformation, but only accounting 1/3 of the lesions, therefore, it cannot be regarded as an independent entity. The cases with desmoplastic pattern were too small; no significant correlation was noted statistically. The expression and correlation of hTR and hTERT in AB was shown in Table 3. It was noted from Table 3 that the expression of hTR and hTERT in AB was positively correlated. Also, the expression of hTR, hTERT and p53 had positive correlation ( $p < 0.001$ , Table 4).

By Pearson correlation analysis, in hTR,  $r_s=0.536$ , the strong positive rate of hTR (+++) was positively correlated with the expression of p53 ( $p<0.001$ ), while in hTERT,  $r_s=0.754$ , the strong positive rate of hTERT (+++) was positively correlated with the expression of p53 ( $p<0.001$ ).

## Discussion

The p53 gene is the most correlative gene with human neoplasms discovered so far. It is generally believed that p53 belongs to tumor suppressor gene. Only when p53 undergoes mutation or interrelation with other proteins, can p53 lose its normal function and promote tumor generation.<sup>2</sup> The wild type p53 exerts negative regulation on cell proliferation. It was demonstrated by massive investigations that telomerase is one of the most specific and sensitive molecular markers for human tumors until now,<sup>3,4</sup> and the activity of telomerase can be used as a marker of malignant tumor and predication of prognosis. The regulation of mechanism of telomerase remains unclear. It was reported that the overexpression of protooncogene C-myc activated telomerase.<sup>5</sup> Antisensedigonucleotides against C-myc can down regulate the activity of telomerase in leukemia cells.<sup>6</sup> Kumamoto et al.<sup>7</sup> showed that C-myc and hTERT had a similar expression in AB. Other study reported that PMA, the agonist of protein kinase C (PKC) can improve the activity of telomerase,<sup>8</sup> bcl-2 and Rb gene were also involved in the event. The expressions of p53 and telomerase were different in various reports, some believed the expressions of p53, hTR and hTERT in malignant tumors were correlated,<sup>9,10</sup> but some found no correlation with p53.<sup>11</sup> The expression of p53, hTR and hTERT in AB and OKC has not been reported previously.

Our study showed that the positive situs of p53, hTR and hTERT were similar in the peripheral and stellate layer of AB, while the keratinized degeneration-shape cells and granular cells were seldom or not stained. This implied that in the same tumor, different cells had different activity and differentiation. Therefore, the expression of p53, hTR and hTERT displayed heterogeneity. The present study confirmed that keratinized degeneration-shape cells and granular cells represent terminal differentiation of cells.<sup>12</sup> Similarly, the activated cells of hTR and hTERT in OKC were mainly situated in the basal layer, other than in the corneal layer, which was in consistence with p53 protein mostly expressing in the basal layer, reflecting a quite high proliferation of cells in the basal layer of OKC, according with the expression of bcl-2.<sup>13</sup> Compared with OKC and normal oral mucosa, the expression of p53 in AB was highest (85.7%, 42/49), the positive rate of hTR and hTERT was as high as 94.4% (51/54), while in malignant AB, hTR and hTERT was 100% strongly positive, and the cells with positive staining of p53 protein increased as well, reaching 300 to 400 in each high power field, which enunciated that the high expression of p53 was in consistence with the strongly positive staining of hTR and hTERT ( $p<0.001$ ). El-Sissy<sup>14</sup> proposed that the overexpression of p53 reflected its important role in tumor growth and carcinogenesis. In one study,<sup>15</sup> the positive staining of p53 was shown significantly stronger in AB than in amelificator and dentate laminae. Invasion is one of the principal biologic characteristics of malignant tumors. Although regarded as benign tumor by WHO, AB has unique biologic behavior, being borderline tumor in fact. Clinically, AB grows invasively like malignant tumors, with a high recurrence rate after intervention. The high expressions of

hTR and hTERT mRNA as well as p53 protein in AB demonstrated in this study provided evidence for its invasive clinical behaviors.

It was demonstrated that the expression of hTR and hTERT was not consistent with the activity of telomerase,<sup>16</sup> however, the expression of hTR and hTERT in AB and OKC was coherent, and related to the high expression of p53 protein. In few cases, the expression of p53 was negative, yet the expression of hTR and hTERT was positive, which indicated that the activity of telomerase was still regulated by other intracellular signal transductions and engaged in carcinogenesis coordinately.

## References

1. Kim NW, Piatyszek MA, Prowse KR, et al. Specific association of human telomerase activity with immortal cells and cancer. *Science* 1994; 266: 2011-5.
2. Finlay CA, Hinds PW, Levine AJ. The p53 proto-oncogene can act as a suppressor of transformation. *Cell* 1989; 57: 1083-93.
3. Mao L, El-Naggar AK, Fan YH, et al. Telomerase activity in head and neck squamous cell carcinoma and adjacent tissues. *Cancer Res* 1996; 56: 5600-4.
4. Califano J, Ahrendt SA, Meiningner G, et al. Detection of telomerase activity in oral rinses from head and neck squamous cell carcinoma patients. *Cancer Res* 1996; 56: 5720-2.
5. Cerni C. Telomeres, telomerase, and myc. An update. *Mutat Res* 2000; 462: 31-47.
6. Fujimoto K, Takahashi M. Telomerase activity in human leukemic cell lines is inhibited by antisense pentadecadeoxynucleotides targeted against c-myc mRNA. *Biochem Biophys Res Commun* 1997; 241: 775-81.
7. Kumamoto H, Kinouchi Y, Ooya K. Telomerase activity and telomerase reverse transcriptase (TERT) expression in ameloblastomas. *J Oral Pathol Med* 2001; 30: 231-6.
8. Bodnar AG, Kim NW, Effros RB, Chiu CP. Mechanism of telomerase induction during T cell activation. *Exp Cell Res* 1996; 228: 58-64.
9. Rogan EM, Bryan TM, Hukku B, et al. Alterations in p53 and p16 INK4 expression and telomerase length during spontaneous immortalization of Li-Fraumeni syndrome fibroblasts. *Mol Cell Biol* 1995; 15: 4745-53.
10. Counter CM, Avilion AA, LeFeuvre CE, et al. Telomerase shortening associated with chromosome instability is arrested in immortal cells which express telomerase activity. *EMBO J* 1992; 11: 1921-9.
11. Iida A, Yamaguchi A, Hirose K. Telomerase activity in colorectal cancer and its relationship to bcl-2 expression. *J Surg Oncol* 2000; 73: 219-23.
12. Kumamoto H, Ooya K. Expression of E-cadherin and alpha-catenin in epithelial odontogenic tumors: an immunohistochemical study. *J Oral Pathol Med* 1999; 28: 152-7.
13. Zhong M, Wang J, Wang ZY. The expression of apoptosis-suppressing gene bcl-2 in odontogenic lesions. *J Modern Stomatol* 2002; 16: 320-3.
14. El-Sissy NA. Immunohistochemical detection of p53 protein in ameloblastoma types. *East Mediterr Health J* 1999; 5: 478-89.
15. Kumamoto H. Detection of apoptosis-related factors and apoptotic cells in ameloblastomas: analysis by immunohistochemistry and an in situ DNA nick end-labeling method. *J Oral Pathol Med* 1997; 26: 419-25.
16. Nakayama J, Saito M, Nakamura H, Matsuura A, Ishikawa F. TLP1: a gene encoding a protein component of mammalian telomerase is a ovel member of WD repeats family. *Cell* 1997; 88: 875-84.

### Reprint request to:

Dr. Ming Zhong  
Department of Pathology, College of Stomatology, China Medical University  
117 Nan Jing North Street, Heping District, Shenyang, 110002, P. R. China  
Fax:+86-24-23410142 E-mail: zhongming1234@163.net

Received January 17, 2004. Revised February 24, 2004. Accepted March 1, 2004.  
Copyright ©2004 by the Editorial Council of the *International Chinese Journal of Dentistry*.