

## Head and neck manifestations of neurofibromatosis: A clinical report

Nadeem Ahmad, DDS,<sup>a</sup> Bushra Ahmad, BDS, MFDS RCS,<sup>b</sup> and Hom-Lay Wang, DDS, MSD<sup>a</sup>

<sup>a</sup>Department of Periodontics/Prevention/Geriatrics, School of Dentistry, University of Michigan, Ann Arbor, MI, USA, and <sup>b</sup>Department of Oral and Maxillofacial Surgery, Kent and Canterbury Hospital, Canterbury, United Kingdom.

Neurofibromatosis type 1 (NF1) or von Recklinghausen's disease is an autosomal dominant set of heritable disorders of ectodermal tissues. This disease affects approximately one in 4,000 births. It causes tumors to grow primarily along nerves, but also on non-nerve-associated tissues resulting in developmental abnormalities. Generally, NF1 is characterized by multiple skin café-au-lait pigmentation lesions, as well as enromas. The anatomical compartmentalization in the head and neck region leads to a multitude of variable clinical presentations, such as asymmetrical pendulous masses, when these areas are afflicted with neurofibromas. In this paper, a patient with NF1 will be used to demonstrate the unique intra- and extra-oral manifestations of this condition. (*Int Chin J Dent* 2003; 3: 69-75.)

**Key Words:** developmental abnormalities, neurofibromatosis, von Recklinghausen's disease.

### Introduction

Neurofibromatoses (NF) are a set of heritable disorders of ectodermal tissues, which often cause tumors to grow along nerves, but also on non-nerve-associated tissues. In 1882, Dr. Friedrich von Recklinghausen first reported NF in a 55-year-old woman with multiple skin lesions associated with patches of cutaneous hyperpigmentation, and was known as von Recklinghausen's disease at that time. So far, eight subtypes of NF have been identified, although only two distinct forms, NF1 and NF2, account for a majority of the cases. Neurofibromatosis 1 (NF1), also known as von Recklinghausen NF or Peripheral NF, is characterized by multiple café-au-lait spots and neurofibromas on or under the skin.<sup>1,2</sup> This subtype typically occurs in 1:4,000 births. Symptoms of NF1 are often evident at birth and almost always by the time a child has reached their first decade of life. Approximately half of people with NF also exhibits learning disabilities.<sup>3,4</sup> Neurofibromatosis 2 (NF2), also known as Bilateral Acoustic NF (BAN), is a much rarer condition occurring only in 1:40,000 births. NF2 is characterized by bilateral tumors on the vestibulocochlear nerve. These tumors cause pressure damage to neighboring nerves, which may lead to headache, facial pain, or numbness. Those affected may also notice some form of hearing impairment as early as their teenage years. Other early symptoms may include tinnitus and poor balance.

Both forms of NF are autosomal dominant genetic disorders which may be inherited from a parent who

has NF or may be the result of a spontaneous mutation. This is one of the highest known mutation rates for any gene-associated disorder. Each child of a parent with NF has a 50% chance of inheriting the gene and developing NF.<sup>5</sup> The type of NF inherited by the child is similar to that of the affected parent, although the clinical manifestations may vary from person to person within a family. NF affects both sexes equally and has no particular racial, geographic, or ethnic distribution. This paper describes a case of a 46 year-old Caucasian female with neurofibromatosis type 1 with the aim of illustrating the clinical intra- and extra-oral manifestations of this disease.

### Clinical Report

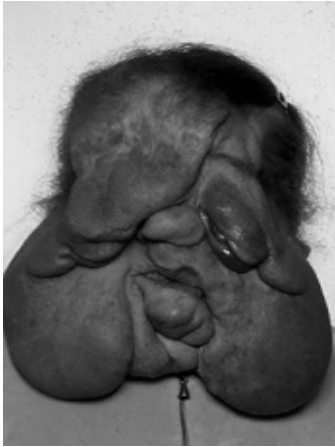A 46 year-old Caucasian female was diagnosed with severe diffuse/plexiform neurofibromatosis type 1 of the head and face, back and hip, heel, and much of her intraoral tissues. Her father, paternal grandmother, and sister were also diagnosed with this same disorder, but to a lesser degree. The NF1 was diagnosed based upon the NIH criteria (Table 1). She was referred to the University of Michigan School of Dentistry for restorative and periodontal care. Her past medical history included at least 20 “debulking” procedures particularly around the perioral region, as well as a deep lobe parotidectomy. She did mention that her condition has increased in severity with age. Her past dental history involved removal of multiple impacted teeth, root canal therapy, amalgam and composite restorations, and fixed porcelain fused-to-metal (PFM) crowns. She has been on a 3-month periodontal maintenance interval for the past 15 years. Overall, her oral status has remained stable over time.

**Table 1.** Two or more of the following criteria are diagnostic for NF 1.

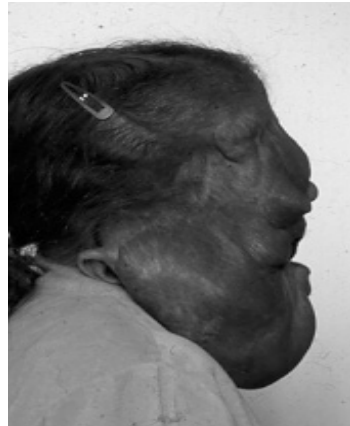- 
- 1 **Neurofibromas** - Two or more, or one plexiform neurofibroma
  - 2 **Café-au-lait macules** - Six or more measuring 5mm in greatest diameter in prepubertal individuals and over 15 mm in greatest dimension in postpubertal individuals
  - 3 **Freckling** - In the axillary or inguinal areas
  - 4 **Optic glioma**
  - 5 **Iris nevi** - Two or more
  - 6 **Sphenoid dysplasia** or thinning of the cortex of the long bones
  - 7 **First-degree relative** (parent, sibling, or offspring)
- 

Palpation and observation of the head and neck regions revealed asymmetrical massive baggy, pendulous masses (*elephantiasis neuromatosa*) on her skin involving the forehead, eyelids, and cheeks (Figs. 1 and 2). Longstanding involvement with her eyes has lead to the loss of her vision. Macrocephaly with skull bossing along the frontal and temporal regions, as well as ocular hypertelorism, downward-slanting palpebral fissures, and low-set ears can also be seen clinically. However, the patient denied any history of

myofacial pain or parafunctional habits.



1

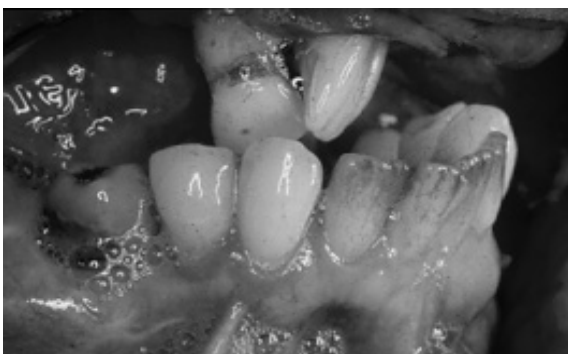


2

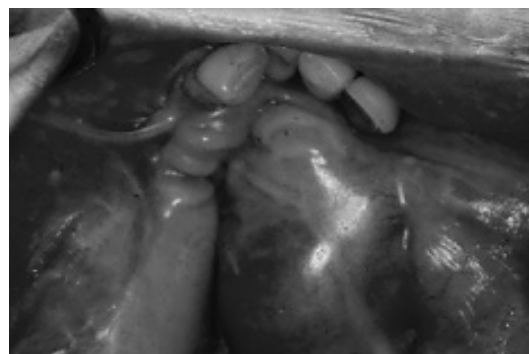**Figs. 1-2.** Frontal and lateral view. Asymmetrical baggy, pendulous masses involving the forehead, eyelids, and cheeks. Note the low-set ears.

Upon intraoral examination, generalized amounts of supragingival with slight subgingival calculus and plaque with staining were found. Heavier amounts were observed on the lingual surfaces of the mandibular anteriors. In general, the patient's oral hygiene was considered fair. She claimed to brush her teeth twice per day using horizontal strokes with a soft electric toothbrush. She did report using Peridex® (0.12% Chlorhexidine) mouthrinse on a daily basis.

Intraoral history and findings included the presence of teeth 8-11, and 20-29. Amalgam and composite restorations were present on teeth 8, 9, 20, 25 and 29, and PFM crowns on 10, and 11. This patient presented with Angle's Class III left canine occlusion. Right excursive movements involved tooth 8 with 27, while left movements involved teeth 10/11 with 21/22. The patient has a unilateral full-arch cross-bite with approximately (-) 7 mm overjet and a 10 mm overbite (100% coverage). Midlines were deviated 6 mm to the left with respect to the mandible. Maximum opening with no pain was 40 mm with 15 mm maximum left and right lateral excursions. Open contacts were noted between teeth: 20/21, 22/23 and 28/29. Teeth 8 and 9 were horizontally overlapped, along with slight crowding in the mandibular anterior region (Fig. 3).



3



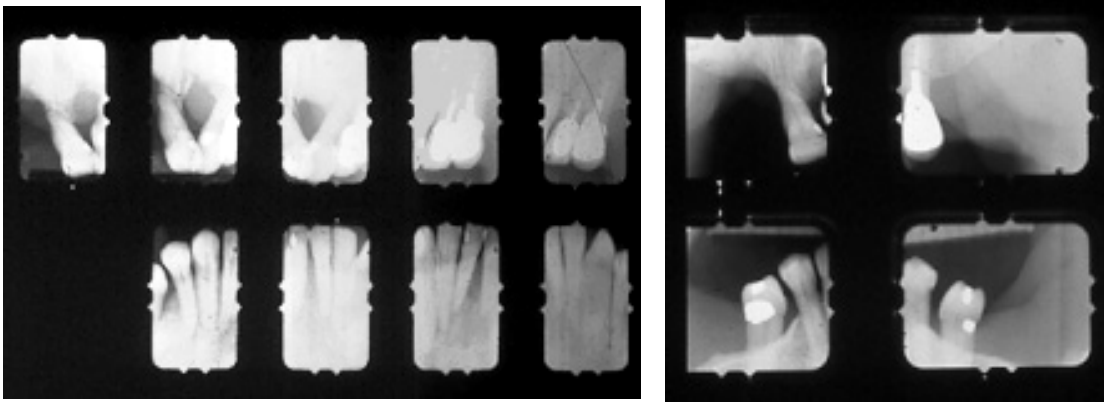
4

**Fig. 3.** Unilateral crossbite with anterior crowding.

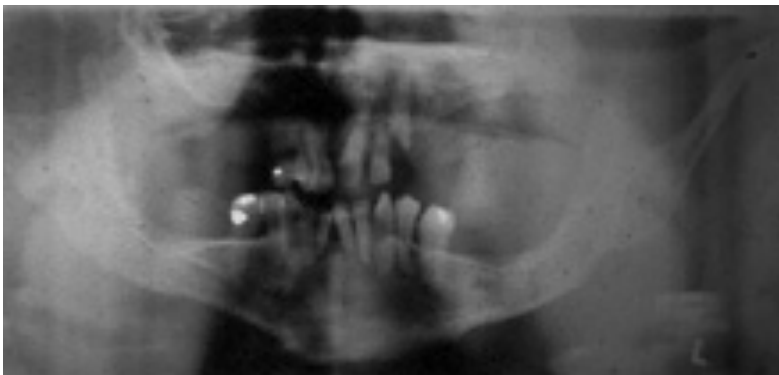
**Fig. 4.** Bulky, elastic, compressible NF tissue along the palate and edentulous ridges.

The palate and edentulous ridges consisted of bulky, elastic, and compressible neurofibromatosis tissue (Fig. 4). This tumor not only filled the palate, but also extended into the buccal vestibule resulting in limited attached gingival tissue. In the mandible, there was adequate attached gingiva between the first bicuspid. Overall, the contours of the free gingival margin were rolled, blunted, slightly edematous, and reddish-pink in appearance. The tissues were slightly inflamed with generalized bleeding on probing on the palatal/lingual surfaces. Generalized recession was noted with up to 6mm observed on tooth 8. Probing depths ranged from 2 to 8 mm. Excessive pseudo-pocketing can be attributed to the tenting effect of the spongy soft tissues. There was no mobility noted beyond physiologic on any teeth. Bilateral mandibular tori were also observed.

Radiographically, interseptal bone loss ranged from about 40 to 95% (Fig. 5). The periodontal ligament space was within normal limits (WNL). Bone trabeculae exhibited a mottled appearance. There was a large radiolucent area at the midline between the maxillary central incisors. Teeth 10/11, 23/24, and 25/26 have close root proximity. Slight generalized loss of crestal lamina dura was noted throughout the dentition. Poor crown:root ratio was seen on teeth 8-11, 24, and 25. Panoramic examination also revealed right and left pneumatized sinuses, a deviated nasal septum, and hypoplastic mandibular condyles (Fig. 6).



**Fig. 5.** Full-mouth series of radiographs demonstrate severe periodontitis and multiple missing teeth.



**Fig. 6.** Panorex demonstrate pneumatized sinuses, deviated nasal septum, and hypoplastic mandibular condyles.

### Discussion

As demonstrated in this case, a patient with NF1 can maintain stable, healthy periodontal conditions as long as regular periodontal maintenance is followed. However, due to the uncertain nature of the progression of this patient's systemic condition, the overall prognosis for the remaining dentition is often regarded as questionable. Long-term prognosis of the maxillary teeth is poor as a result of the already widespread involvement of the tissues by this benign tumor. Regarding her mandibular dentition, the long-term prognosis is fair, provided that the tumor does not extend into the tissues surrounding these teeth. This case illustrates the destructive nature of this tumor on bone, therefore compromising the periodontal support of the remaining teeth.

Neurofibromatosis 1 (NF1) is characterized by spots of increased skin pigmentation, combined with peripheral nerve tumors, and a variety of other dysplastic abnormalities. This disease is an extremely variable disorder. It is not only observed between unrelated patients, but also among affected individuals within a single family, and even at different times in life within a single patient.<sup>1,6,7</sup> The severity of NF ranges from mild (~60%) in which the only signs may be multiple café-au-lait spots and skin neurofibromas, to more severe cases where more serious complications may evolve (~20%). Many of the serious problems in NF are evident at birth that may include congenital defects of the bone, scoliosis, optic glioma and neurological impairment leading to some form of learning disability. Currently, there is no way to accurately predict how seriously affected a person with NF will be, or which complications he or she may develop.

The NIH Consensus Conference had developed diagnostic criteria for NF1, acceptable for routine clinical applications.<sup>8,9</sup> However, limitations of adequately diagnosing NF are mainly directed towards small children without an accurate family history.<sup>10</sup> Molecular genetic testing of the NF1 gene, located on long arm of chromosome 17 at band 17q11.2, is also another tool available for diagnostic purposes.

Approximately half of the patients with NF1 meet the NIH criteria for diagnosis by year one, but almost all do by their first decade of life because many features of NF1 increase in incidence with age.<sup>6,7,11-13</sup> Children who have inherited NF1 can usually be identified within the first year of life because diagnosis requires just one clinical characteristic in addition to a positive family history. This feature is usually multiple café-au-lait spots, which develop at birth in more than 95% of patients with NF1.<sup>13</sup>

Neurofibromas of NF1 often results in bodily enlargement, and may possibly lead to disfigurement. Neurofibromas are painless, slow-growing, non-contagious, benign growths which typically develop on the skin, but may also occur in deeper areas of the body as noted in this patient. Neurofibromas are composed of nerve and fibrotic tissue. Onset is typically around puberty although they may develop at any age.<sup>14</sup> Three forms of NF are of particular importance: fibroma molluscum, elephantiasis neuromatosis, and plexiform neurofibroma.<sup>15</sup> Fibroma molluscum occurs as multiple nodules in the subcutaneous tissues. They consist of small nerve fibers and sheath cells that surround, but do not displace skin appendages. Elephantiasis neuromatosis are diffuse proliferations of Schwann cells and axons, which leads to massive,

disfiguring enlargements of a limb or some other body part. Plexiform neurofibromas are also diffuse enlargements of peripheral nerve sheath cells and fibers. There is a tendency for these lesions to involve major nerve trunks particularly in the orbit, neck, back, and inguinal areas. In this particular case, both elephantiasis neuromatosis and plexiform neurofibromas were observed in the head and neck regions. Some neurofibromas, depending on their location and size, can be removed surgically if they become painful, or because they are cosmetically displeasing. Relapse of a new tumor occasionally appears, particularly if the original tumor was not entirely removed. Currently, there is no evidence that removal of growths will increase the rate of appearance of new growths, or the possibility that partly removed tumors can change from benign to cancerous lesions.

Café-au-lait spots are flat, pigmented spots on the skin. People with NF almost always have six or more spots. The size of the spots varies from 5 mm in children to 15 mm in adults. However, these spots are capable of extending several inches or larger in diameter. Café-au-lait spots are usually present at birth and may increase with age. The spots usually darken as the child ages. Smaller pigmented spots, which may be difficult to discriminate from ordinary freckles, may also be present. However, axillary freckling (Crowe's sign) is considered a strong diagnostic indicator of NF.

An optic glioma is a tumor of the optic nerve. This uncommon growth usually develops in the first four years of life, and is first noticed because of failing vision or bulging of the eye as observed in this case. Surgical intervention along with radiation therapy may be necessary for treatment. Iris hamartomas (also called Lisch nodules) are clumps of pigment in the iris. They do not cause any visual problems, but their presence is helpful in confirming a diagnosis.

The varieties of bone defects seen in NF1 are usually congenitally evident at birth. Defects can occur in almost any bone, but are most often seen in the skull and limbs. They include congenital absence of the orbital wall (dysplasia), which may cause slight bulging of the skin around the eye as observed in this case. It has been estimated that approximately 25% of all neurofibromas are found in the head and neck region.<sup>16</sup>

The life expectancy of patients with NF1 is reduced by at least 15 years.<sup>17</sup> Malignancy and hypertension are main contributors to the increased morbidity seen in adult NF1 patients. Those with only mild and cosmetic symptoms of the disease seem to fare better. So far, there are no specific treatments for NF1 or any drug therapies that can prevent or treat the growth of neurofibromas. However, most of the people affected with neurofibromatosis will not develop major complications. Regular annual visits is recommended to identify any unsuspecting complications early.

This particular case is very challenging because no prosthodontic reconstruction is practical to rehabilitate this minimally existing dentition. Limiting factors in this case can be attributed to the progressive nature of this disease process, as well as the clinician's capability to re-establish the dentition to a state of health and function. Therefore, a multidisciplinary approach will be essential in meeting these objectives.

## References

1. Friedman JM, Riccardi VM. Clinical epidemiological features. In: Friedman JM, Gutmann DH, MacCollin M, Riccardi VM (eds) Neurofibromatosis: Phenotype, natural history, and pathogenesis. Baltimore: Johns Hopkins University Press; 1999. p. 29-86.
2. Rasmussen SA, Friedman JM. NF1 gene and neurofibromatosis 1. Am J Epidemiol 2000; 151: 33-40.
3. North KN, Riccardi V, Samango-Sprouse C, et al. Cognitive function and academic performance in neurofibromatosis. 1: consensus statement from the NF1 Cognitive Disorders Task Force. Neurology 1997; 48: 1121-7.
4. North K. Cognitive function and academic performance. In: Friedman JM, Gutmann DH, MacCollin M, Riccardi VM (eds) Neurofibromatosis: Phenotype, natural history, and pathogenesis. Baltimore: Johns Hopkins University Press; 1999. p. 162-89.
5. Lazaro C, Gaona A, Lynch M, Kruyer H, Ravella A, Estivill X. Molecular characterization of the breakpoints of a 12-kb deletion in the NF1 gene in a family showing germ-line mosaicism. Am J Hum Genet 1995; 57: 1044-9.
6. Huson SM. Neurofibromatosis 1: a clinical and genetic overview. In: Huson SM, Hughes RAC (eds) The Neurofibromatoses: A pathogenetic and clinical overview. London: Chapman and Hall Medical; 1994. p. 160-203.
7. Friedman JM, Birch PH. Type 1 neurofibromatosis: a descriptive analysis of the disorder in 1,728 patients. Am J Med Genet 1997; 70: 138-43.
8. Gutmann DH, Aylsworth A, Carey JC, et al. The diagnostic evaluation and multidisciplinary management of neurofibromatosis 1 and neurofibromatosis 2. J Am Med Assoc 1997; 278: 51-7.
9. NIH Consensus Development Conference. Neurofibromatosis. Conference statement. Arch Neurol 1988; 45: 575-8.
10. DeBella K, Szudek J, Friedman JM. Use of the national institutes of health criteria for diagnosis of neurofibromatosis 1 in children. Pediatrics 2000; 105: 608-14.
11. DeBella K, Poskitt K, Szudek J, Friedman JM. Use of "unidentified bright objects" on MRI for diagnosis of neurofibromatosis 1 in children. Neurology 2000; 54: 1646-51.
12. Wolkenstein P, Freche B, Zeller J, Revuz J. Usefulness of screening investigations in neurofibromatosis type 1. A study of 152 patients. Arch Dermatol 1996; 132: 1333-6.
13. DeBella K, Szudek J, Friedman JM. Use of the national institutes of health criteria for diagnosis of neurofibromatosis 1 in children. Pediatrics 2000; 105: 608-14.
14. Dugoff L, Sujansky E. Neurofibromatosis type 1 and pregnancy. Am J Med Genet 1996; 66: 7-10.
15. Shack RB, Reilley AF, Lynch JB. Neurofibromas of the head and neck. Southern Med Assoc J 1985; 78: 801-4.
16. Peetermans JFE, Van de Heyning PH, Parizel PM, et al. Neurofibroma of the vagus nerve in the head and neck: A case report. Head and Neck 1991; 13: 56-61.
17. Zoller M, Rembeck B, Akesson HO, Angervall L. Life expectancy, mortality and prognostic factors in neurofibromatosis type 1. A twelve-year follow-up of an epidemiological study in Goteborg, Sweden. Acta Derm Venereol 1995; 75: 136-40.

### Reprint request to:

Dr. Hom-Lay Wang

Department of Periodontics/Prevention/Geriatrics, School of Dentistry, University of Michigan  
1011 North, University Ave., Ann Arbor, MI 48109-1078, USA.

FAX: +1-734-764-9148 Email: homlay@umich.edu

Received on July 18, 2003. Revised on August 12, 2003. Accepted on August 15, 2003.

Copyright ©2003 by the Editorial Council of the *International Chinese Journal of Dentistry*.