

## Application of magnetic attachment for connecting a fixed partial denture and a detachable gingiva: A clinical report

Shinsuke Sadamori, DDS, PhD, Seicho Makihira, DDS, PhD, Nobuyuki Nakai, DDS, PhD, and Taizo Hamada, DDS, PhD

Department of Prosthetic Dentistry, Division of Cervico-Gnathostomatology, Graduate School of Biomedical Sciences, Hiroshima University, Hiroshima, Japan

Magnetic attachments have been applied for various prostheses. In this report, a fixed partial denture (FPD) to which a detachable gingiva was connected by magnetic attachment was fabricated to support esthetic recovery of the alveolar bone defect and the maxillary anterior missing teeth. Missing teeth, accompanied with an alveolar bone defect, are generally recovered with a removable denture or with a combination of surgical treatment and a conventional FPD without a detachable gingiva. However, surgical treatment was avoided by utilizing a magnetic system for connection between the FPD and the detachable gingiva. The detachable gingiva made it possible for the patient to maintain oral hygiene by himself. Therefore, this clinical report suggests that a detachable magnetic connection is an alternative technique to avoid surgical treatment and promote oral hygiene in the esthetic restoration required for remarkable alveolar bone defects. (Int Chin J Dent 2006; 6: 89-92.)

**Key Words:** attachment, detachable gingiva, magnet.

### Introduction

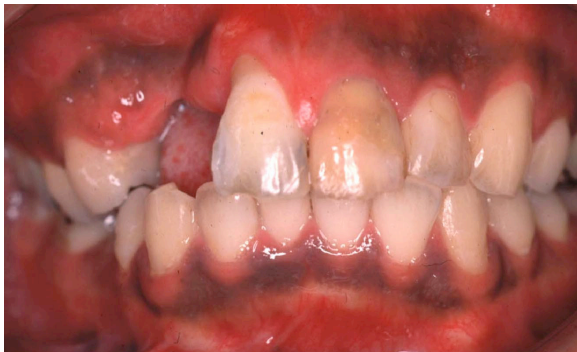Alveolar bone defect and loss of interdental papillae caused by accidents and periodontal diseases can be restored by surgical and prosthetic approaches. The surgical options are auto-connective tissue transplantation,<sup>1</sup> auto-bone graft,<sup>2</sup> and bone substitute-transplantation.<sup>3</sup> Soft tissue transplantations for the localized alveolar ridge defect have been done often and are evaluated to be greatly useful. On the other hand, in the operation of auto-bone graft to the remarkable bone defect, a great deal of pain may be caused to patients. Engineered bone, using bone marrow cells, may help the treatment of such remarkable bone defects. However, the technique of hard tissue engineering has not yet been established. Alternatively, missing teeth and tissues can be replaced with a detachable gingival extension connected to an implant-supported prosthesis with precision attachments.<sup>4</sup> The implant system requires surgical treatment, but not preparation of the abutment teeth.

Prosthetic treatment is considered to be another option if patients desire to avoid surgical risks. Cura et al. reported an excellent clinical case of the technique of esthetic connection between a fixed partial denture (FPD) and a detachable gingival extension to compensate for an enormous alveolar bone defect.<sup>5</sup> This useful connection was a custom-made precision attachment. We recovered the remarkable alveolar bone defect by a detachable gingiva connected to a FPD using magnetic attachment. This magnetic connection is also esthetic. The concept of our magnetic method is consistent with Cura's concept for a simple fixed prosthesis, though the system of each esthetic connection differs.<sup>5</sup> The purpose of our new fabrication means that the detachable gingival extension, as a replacement for the missing soft tissue on bone defect, helps patients to maintain hygiene around the alveolar bone defect, and to keep the FPD clean. Patients can avoid surgical treatments possibly involving high risks. We describe here a novel application of an improved magnetic attachment for the FPD.

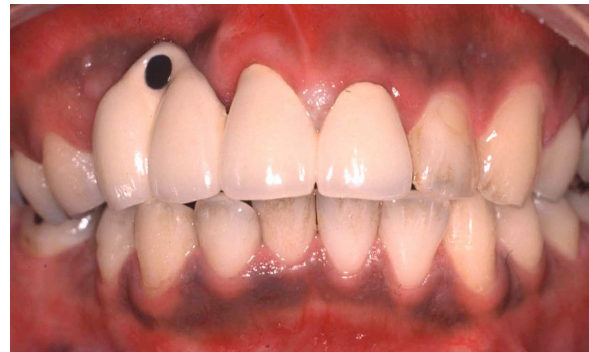### Clinical Report

A 28-year-old man injured his face in a traffic accident. The alveolar bone, periodontal tissues and teeth were clinically examined. Maxillary right lateral incisor and canine teeth were extracted in the Department of Oral

Surgery of our hospital. Pulpectomy of the maxillary central incisors was carried out because of deep caries at Department of Periodontology. The patient was diagnosed to have an accidentally injured remarkable bone defect, and a loss of soft tissue, that would need an esthetic recovery (Fig. 1).



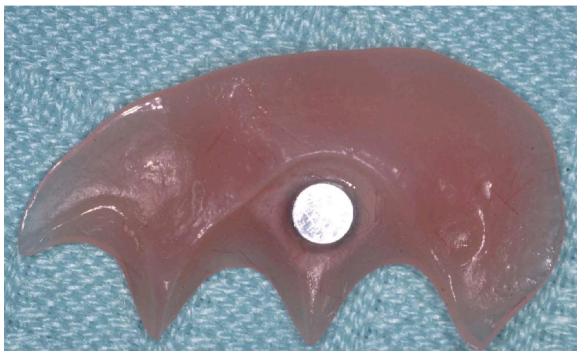
1



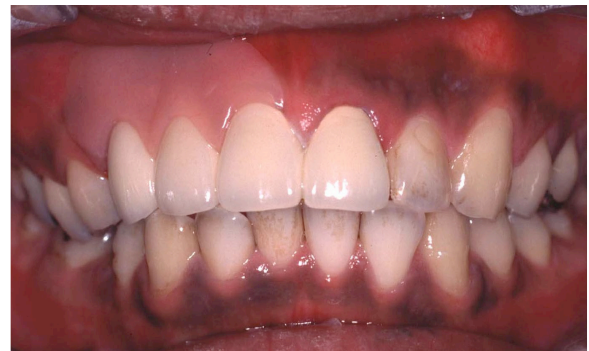2

**Fig. 1.** View of remarkable alveolar bone defect.

**Fig. 2.** Fixed partial denture to which the magnet keeper was bonded.



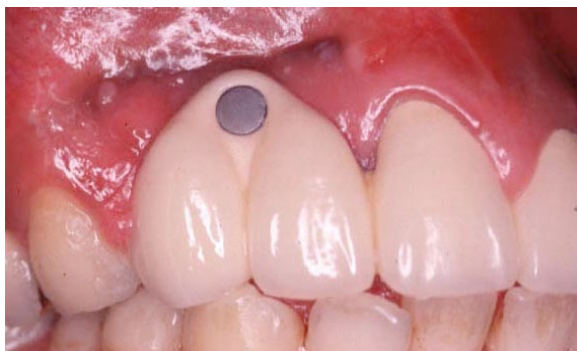3



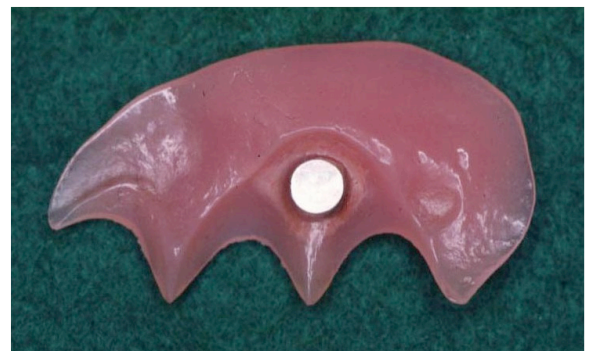4

**Fig. 3.** Detachable polymerized resin-gingiva in which the magnet was buried.

**Fig. 4.** Fixed partial denture and removable gingival extension set in place.



5



6

**Fig. 5.** Fixed partial denture with the magnet keeper in follow-up, after 2 years.

**Fig. 6.** Detachable gingiva part after 2 years.

At first, the provisional restoration made with ivory-colored resin for the missing teeth was set on the abutment teeth of the maxillary incisors and right premolars without a gingiva, since the patient desired neither a conventional partial (removable and fixed) denture with a gingiva, nor, a surgical treatment including implants. However, this temporary fabrication was not acceptable to the patient. The patient was not pleased about no cover over the bone defect, and complained of food impaction into bone defect area. The problems were discussed and we proposed a novel prosthesis using an improved magnetic attachment at the level of size and force. The patient understood the expected advantages and disadvantages of the magnet system. Patient finally

preferred a simple fabrication, combined with a FPD, a removable gingival extension, and a magnetic attachment.

We fabricated a porcelain-fused-to-metal FPD and a gingival extension in accordance with the manufacturer's method, which were detachably connected by a magnetic attachment system (Hyper Slim Direct Bonding Keeper Set, J. Morita, Suita, Japan). In brief, after a metal framework was completed, Direct Bonding (DB) keeper housing pattern was set on a metal framework in order to secure a space for the magnet keeper (diameter 3.0 mm, thickness 0.8 mm, Morita), prior to build-up of the porcelain. The DB keeper housing pattern was burnt out when the porcelain was built up and burned. The magnet keeper was bonded to the lower portion of the ceramic pontic using Super-Bond C&B (Sun Medical, Moriyama, Japan) (Fig. 2). We polymerized the artificial gingiva with the use of pink-colored denture base resin (Palapress Vario, Heraeus Kulzer, Hanau, Germany). This polymerization was carried out in the presence of the improved magnet assembly (diameter 3.0 mm, thickness 1.3 mm, attractive force 3.9 N, Morita), resulting in the magnet being fixed on the gingival side of the thin polymerized resin-gingiva (Fig. 3). Though this patient did not desire reappearance of melanin pigments, some efforts will be normally required to make melanin-like stain on polymerized resin-gingiva part.

The detachable function of these fabrications is theoretically permanent, by means of magnetic force (Figs. 2-4). The patient received an explanation about the nature of the magnet, and was instructed in daily use, important for maintenance. The patient understood enough how to wear them. In 2 months, the patient was accustomed to use of the prostheses, and described satisfaction with the magnetic connection, because he could set the gingival extension, and remove it from the FPD by himself, at anytime, and because he had less food impaction.

After 2 years, the patient was asked about the condition of the magnet system, and was thoroughly examined. The patient had no complaints about a decrease in attractive force, and felt comfortable wearing the fabrications. No obvious changes around bone defect or the abutment teeth were clinically observed in comparison with the initial state of seating (Figs. 5 and 6).

## Discussion

Cura et al. indicated a novel method to esthetically recover alveolar bone defect using a detachable gingival extension. They utilized a custom-made pin system (rather than intra- or extracoronal attachment) as a connection of partial denture and detachable gingiva.<sup>5</sup> In this case, we applied a magnetic attachment for an alternative connection to combine such prostheses, suggesting that a magnetic attachment is also for connecting a detachable gingiva and a fixed partial denture, as well as the custom-made pin system.

It is possible to fabricate magnetic attachments for dental prostheses which are comparable in holding power to conventional mechanical precision attachments. The obvious advantage is that magnetic attachments do not need complicated coplanar surfaces and springs which are expensive to fabricate and require frequent adjustment or replacement with use.<sup>6</sup> Magnet systems are not complicated, however, the size and the corrosion of magnets are considered to be important limiting factors in the use of magnets intraorally. Magnets have been reduced to an acceptable size for intraoral use. A numbers of magnetic retentive appliances have been developed, but almost all are rarely used, because of their low retentive force, corrosion, and large size.<sup>7,8</sup> These problems were solved with the magnetic attachment developed, and is a sure retainer of position for dentures.<sup>9,10</sup> The size of the improved magnet and keeper used here was likely acceptable, as expected, for the limited space intraorally,

including the thin extended pontic and gingiva as shown in Figs. 2 and 3.

The magnet we used is made from neodymium-iron-boron and its capability is theoretically permanent.<sup>11</sup> However, rare-earth magnets like neodymium-iron-boron, are susceptible to corrosion, and have been shown to break down in the oral cavity.<sup>8</sup> Various coating procedures (parlylene coating, and stainless steel casing sealed with epoxy resin, welding, or laser welding) have been employed to seal them off from the harsh intraoral environment.<sup>12,13</sup> In a 2-year follow up, no corrosion was observed on the surface of the magnet (Fig. 6). The magnet was covered with the high anticorrosion stainless steel and seams were laser welding. This laser welding was effective in protecting against corrosion.

Patients had no complaints about the reduction of magnetic force. An advantage of magnetic retainers over mechanical attachments is that they do not wear and fail within an increasing number of break-way cycles, and can remain functional indefinitely as long as they do not corrode.<sup>6</sup> Our case indicated that the improved magnet had kept its force for two years intraorally, supporting the finding that our magnet treated with laser welding had no corrosion.

In conclusion, this clinical report indicates that a detachable prosthesis by magnet is a novel technique to avoid surgical treatment, to recover remarkable alveolar bone defects and missing teeth. Development of a smaller and more powerful magnetic attachment could be required. Magnets could possibly be applied to various other prostheses in the oral cavity.

#### Acknowledgement

This study was supported in part by a Grant-in-Aid for Scientific Research (16390617) from Japan Society for the Promotion of Science (JSPS).

#### References

1. Studer S, Naef R, Scharer P. Adjustment of localized alveolar ridge defects by soft tissue transplantation to improve mucogingival esthetics: a proposal for clinical classification and an evaluation of procedures. *Quintessence Int* 1997; 28: 785-805.
2. Buser D, Dula K, Belser UC, Hirt HP, Berthold H. Localized ridge augmentation using guided bone regeneration. II. Surgical procedure in the mandible. *Int J Periodontics Restorative Dent* 1995; 15: 10-29.
3. Gray JL, Quattlebaum JB. Correction of localized alveolar ridge defects utilizing hydroxyapatite and a "tunneling" approach: a case report. *Int J Periodontics Restorative Dent* 1988; 8: 72-8.
4. Brygider RM. Precision attachment-retained gingival veneers for fixed implant prostheses. *J Prosthet Dent* 1991; 65: 118-22.
5. Cura C, Saracoglu A, Cotert HS. Alternative method for connecting a removable gingival extension and fixed partial denture: a clinical report. *J Prosthet Dent* 2002; 88: 1-3.
6. Jackson TR, Healey KW. Rare earth magnetic attachments: the state of the art in removable prosthodontics. *Quintessence Int* 1987; 18: 41-51.
7. Drago CJ. Tarnish and corrosion with the use of intraoral magnets. *J Prosthet Dent* 1991; 66: 536-40.
8. Riley MA, Williams AJ, Speight JD, Walmsley AD, Harris IR. Investigations into the failure of dental magnets. *Int J Prosthodont* 1999; 12: 249-54.
9. Mizutani H, Nakamura K, Ai M. Follow-up study of removable partial denture with magnetic attachment by questionnaire to dentist. *J Jpn Prosthodont Soc* 1997; 41: 902-9.
10. Thean HP, Khor SK, Loh PL. Viability of magnetic denture retainers: a 3-year case report. *Quintessence Int* 2001; 32: 517-20.
11. Vardimon AD, Graber TM, Drescher D, Bourauel C. Rare earth magnets and impaction. *Am J Orthod Dentofacial Orthop* 1991; 100: 494-512.
12. Walmsley AD, Brady CL, Smith PL, Frame JW. Magnet retained overdentures using the Astra dental implant system. *Br Dent J* 1993; 174: 399-404.
13. Noar JH, Wahab A, Evans RD, Wojcik AG. The durability of parlylene coatings on neodymium-iron-boron magnets. *Eur J Orthod* 1999; 21: 685-93.

#### Correspondence to:

Dr. Shinsuke Sadamori  
 Department of Prosthetic Dentistry, Division of Cervico-Gnathostomatology  
 Graduate School of Biomedical Sciences, Hiroshima University  
 1-2-3, Kasumi, Minami-ku, Hiroshima 734-8553, Japan  
 Fax: +81-82-257-5682 E-mail: tsada@hiroshima-u.ac.jp

Received May 17, 2006. Accepted June 3, 2006.

Copyright ©2006 by the *International Chinese Journal of Dentistry*.